

# Archaeological evidence for 18th-century medical practice in the Old Town of Edinburgh: excavations at 13 Infirmary Street and Surgeons' Square

David Henderson\*, Mark Collard\* & Daniel A Johnston†

## ABSTRACT

*Articulated human skeletons and disarticulated bones recovered in 1993 from excavations in the area of the former Lady Yester's Kirkyard showed clear evidence of post-mortem dissection. They are identified as the 'unclaimed' dead buried by the Royal Infirmary in the second half of the 18th century. There was evidence for post-mortem tooth removal from all the dentitions recovered during the excavation, probably for the manufacture of sets of false teeth. A further assemblage of human bones, found in 1988 adjacent to 18th/19th-century anatomy schools formed part of a teaching collection from the schools.*

## INTRODUCTION

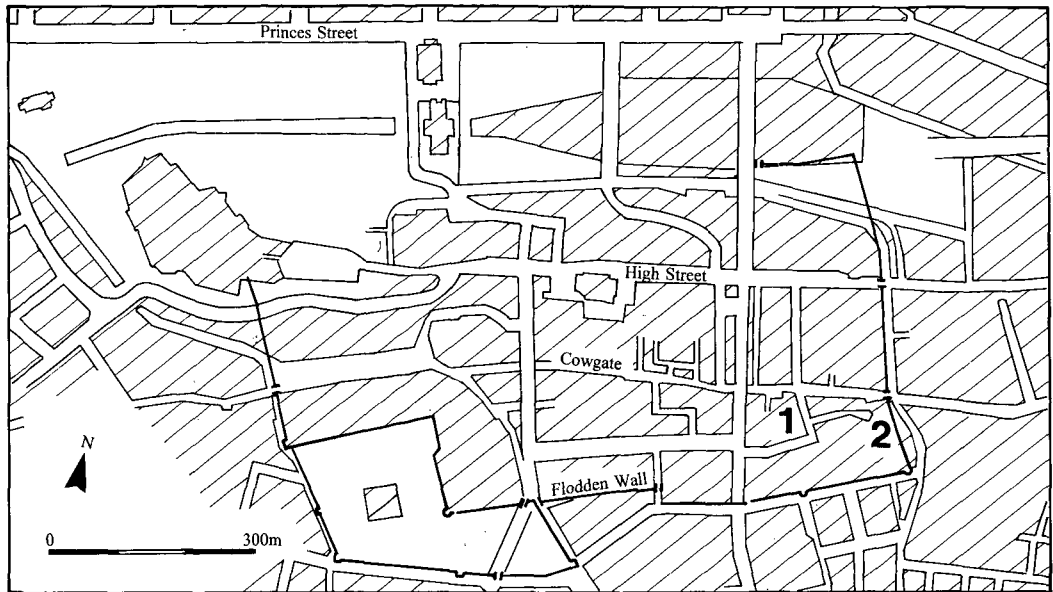
This report describes two investigations (illus 1) carried out by the Archaeology Service of the City of Edinburgh District Council in the south-east quarter of the Old Town of Edinburgh. Both produced human bone which, when examined, provided evidence of medical practice in later post-medieval Edinburgh. The full site archive and a detailed report on the skeletal remains has been deposited in the National Monuments Record of Scotland (RCAHMS), Edinburgh.

## 13 INFIRMARY STREET

In December 1992 contractors carrying out underpinning operations on behalf of the University of Edinburgh at 13 Infirmary Street, Edinburgh (NT 2608 7343), uncovered human skeletal remains beneath an internal wall of the building. D A Johnston of the Archaeology Service of the City of Edinburgh District Council investigated and excavated the remains. Subsequently excavations for the installation of a lift-shaft in an adjacent room uncovered further human bone and the area affected was excavated by M Collard & D A Johnston in January 1993. In September 1993 a small amount of disarticulated human bone was recovered by J A Lawson from excavations in the northern part of the building.

\* Edinburgh City Council Archaeology Service, 10 Broughton Market, Old Broughton, Edinburgh EH3 6NU

† 24 Swaine Hill Crescent, Yeadon, Leeds LS19 7HE



ILLUS 1 The location of the excavations at 13 Infirmary Street (1) and Surgeons' Square (2). (Based on the Ordnance Survey map © Crown Copyright)

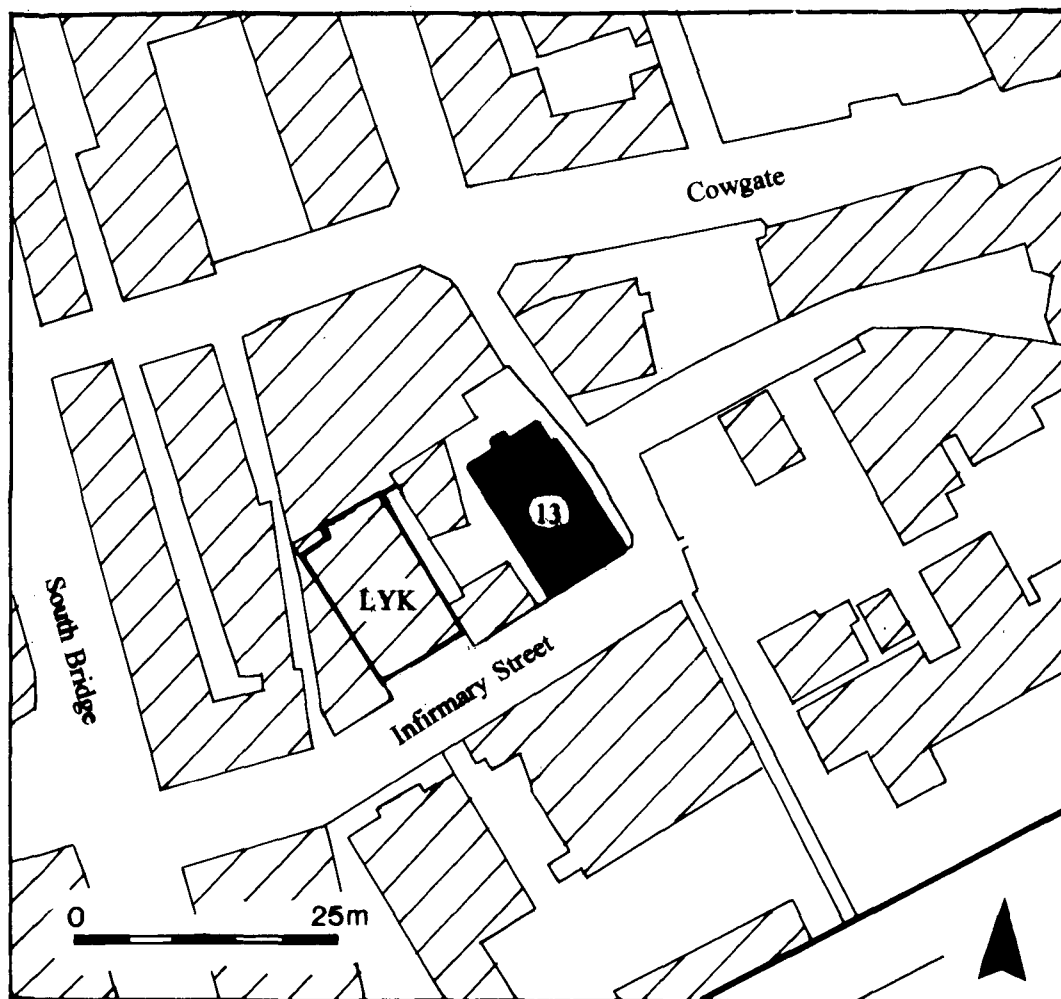
#### SITE HISTORY (ILLUS 1, 2 & 3)

The site lies within the north-western part of the former precinct of the medieval Blackfriars Monastery, on the west side of a transe (later High School Wynd) which gave access to the monastery from the Cowgate. The lands of Blackfriars passed to the Town Council of Edinburgh in 1563 (Cowan 1912, 68).

In 1635 the Town Council of Edinburgh resolved to construct two new churches, only one of which was built – the Tron Kirk on the High Street. The second, on Castlehill, was never completed. Instead, as a result of a total donation of 16,000 merks by Margaret, Lady Hay of Yester, a church was erected on the west side of High School Wynd, on the corner of the street later known as Infirmary Street. The kirk was completed in 1647, and is visible on the view of Edinburgh drawn by Gordon of Rothiemay in the same year. The form of the church is not particularly clear on Gordon's plan, but it is set within a precinct, surrounded by a wall. On William Edgar's measured plan of 1765 (illus 3) the church is clearly cruciform and is surrounded by a kirkyard wall, with two entrance gates on the east side.

In 1748 the construction of the Royal Infirmary of Edinburgh (illus 3) was completed on the ground immediately to the south of the kirk. In 1749 the managers of the hospital asked the Town Council 'to allot a small portion of the Lady Yester's Churchyard for burial of the dead of the Royal Infirmary' (Cowan 1912, 89). This was granted with the condition that the managers were, in their interments, 'to keep at a distance from the walls, because they were disposed for private burying places'.

The kirk itself continued in use for the rest of the 18th century but was derelict by 1803, when it was condemned as unsafe by the Town Council. A new church, also called Lady Yester's Kirk, was completed by 1805. This lay 30 m to the west of the original site, along Infirmary Street, and the secularized building still stands (illus 2). The old site was vacant until 1821 (only the churchyard

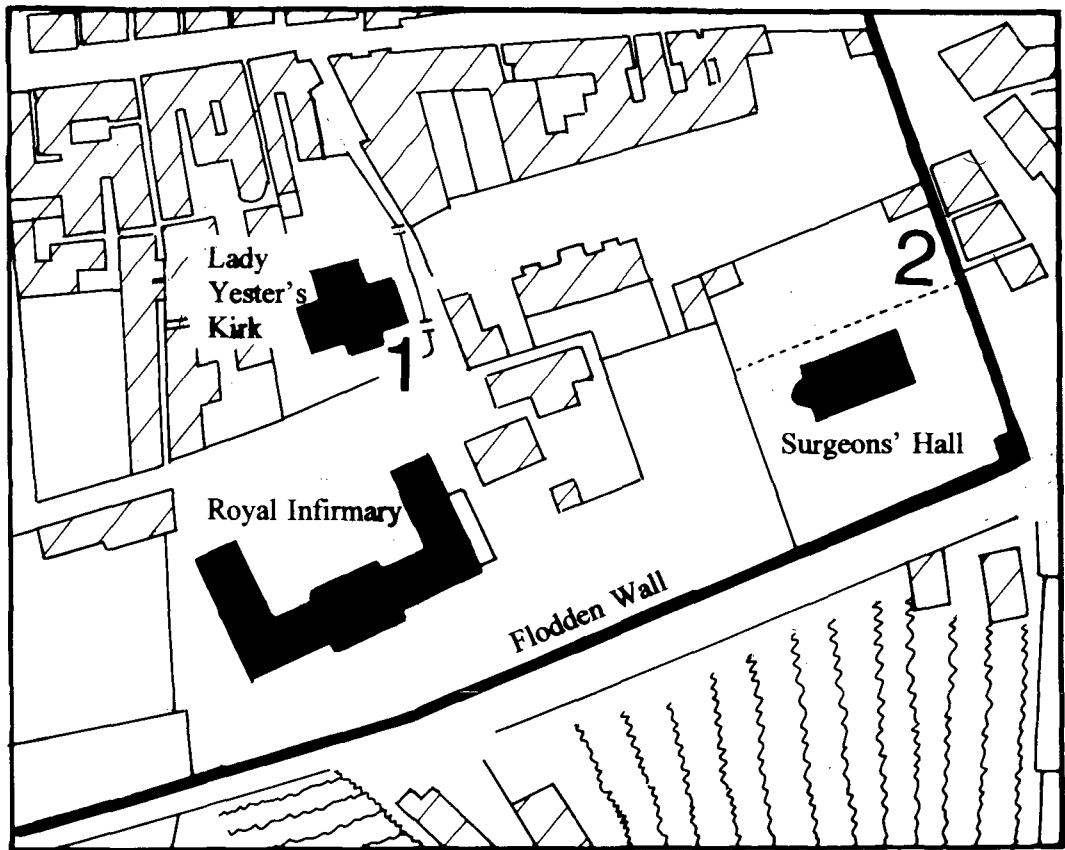


ILLUS 2 The location of 13 Infirmery Street and the Second Lady Yester's Kirk (LYK: now a secularised building)

is marked on Kirkwood's map of 1817, no buildings are shown) when a new church was built by a congregation of Seceders. The feu grant reserved a right of access to the 'Burying Vault at the north end of the ground' where tombstones survived at the time of Cowan's writing. Since then, the building has had a wide variety of owners but the only substantial structural alteration has been the addition of a single-storey extension against the original façade (Gifford, McWilliam & Walker 1984, 229).

#### EXCAVATION RESULTS: AREA A (ILLUS 4, 5 & 6)

The area excavated measured 3.6 m by 3.4 m. All material within this was removed down to a depth of 1.5 m below ground level within the building. Six *in situ* skeletons were excavated, in varying degrees of survival. In addition a group of foot bones at the west end of the trench probably indicates



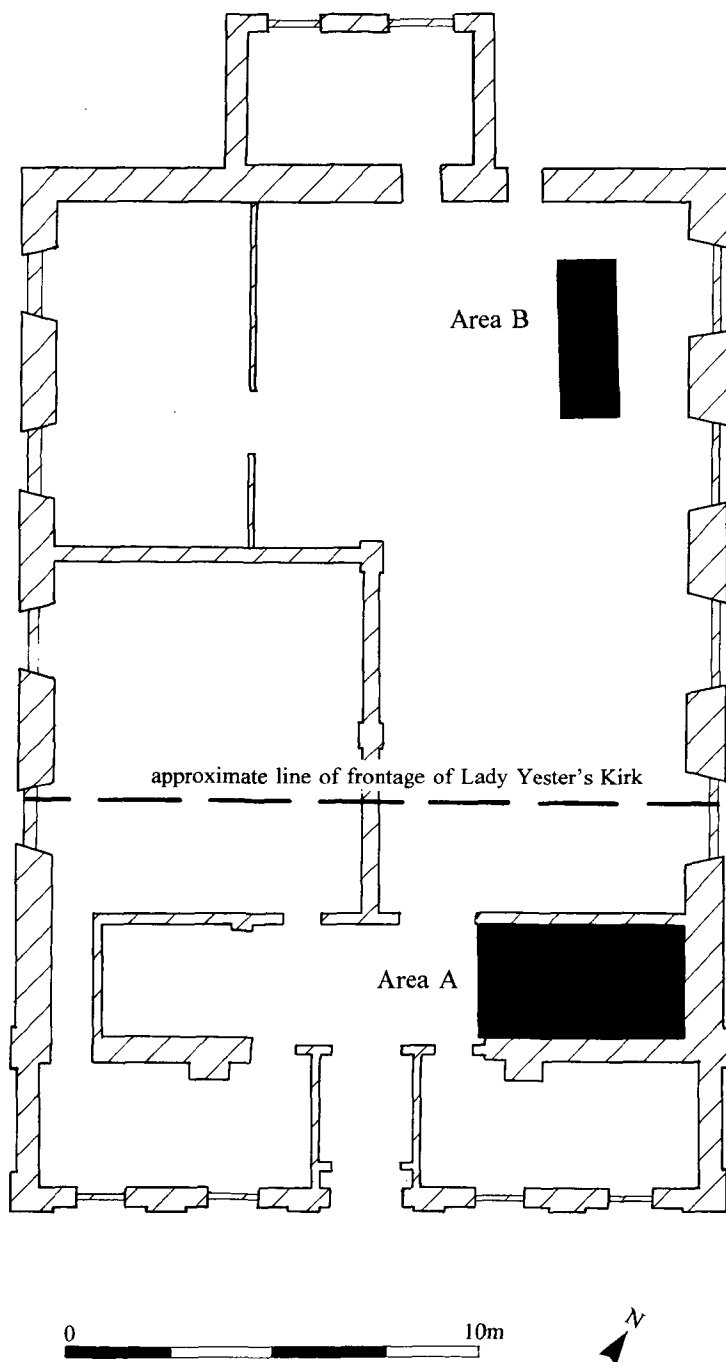
ILLUS 3 The first Lady Yester's Kirk, Surgeons' Hall and the Royal Infirmary, based on a plan of 1765 by William Edgar. The Kirk is no longer extant.

the existence of a further burial; a line of preserved wood to the south of these was interpreted as the foot-end of a coffin. Neither of these features were removed as they lay close to the section edge, and were to be left undisturbed by the subsequent building works. Discrete groups of redeposited disarticulated human bone were found through the excavated deposits.

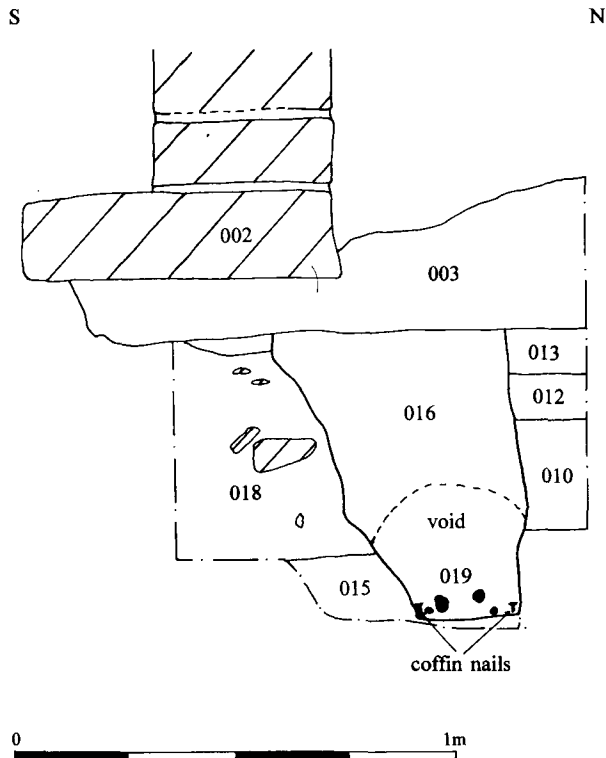
#### *Stratigraphy (illus 5)*

The natural subsoil of a reddish-brown glacial till and an outcrop of sandstone bedrock were exposed in the southern part of Area A and the burials in this area were just cut into its upper surface. North of this the natural ground level sloped away towards the Cowgate valley, and the burials in this area were cut into anthropogenic deposits. All the inhumations were found at approximately the same level below modern ground surface, c 1.50 m.

Owing to the contractors' working methods and the usual problem of discerning grave cuts where the fill of the grave is of the same material as the deposits through which it is cut, the only observable stratigraphy was seen in section in the initial underpinning trenches but this was sufficient to demonstrate the sequence of activity. The burials beneath the wall footing (SK 001 & 019) were both within grave cuts, 0.65 m deep, cut through accumulated deposits of dark loams with oyster shell and rubble; these were visible as stratified deposits



ILLUS 4 The excavated areas (A and B) at 13 Infirmary Street



ILLUS 5 13 Infirmery Street: section through deposits underlying the wall footing at the north side of Area A

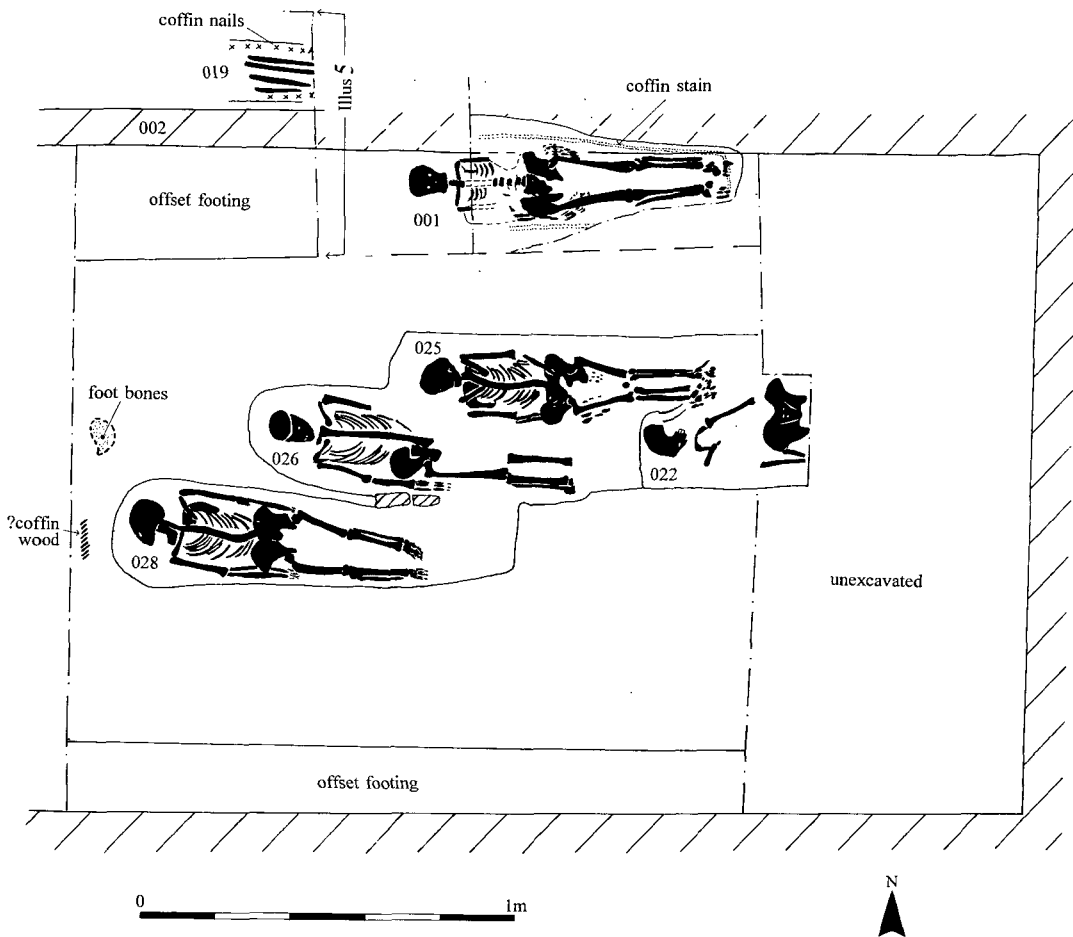
on the north side of the graves (L 010, L 012 & L 013) while to the south they were very mixed (L 018), the result of repeated excavation and redeposition within the area of burials. These deposits and the graves were sealed by a deposit of rubble and mortar (L 003) on which the existing internal wall (F 002) of the building was constructed. This was raised on stone footings and was built of rubble with some areas of hand-made bricks. It was the dividing wall between the original entrance area and the main body of the 19th-century chapel prior to the construction of the extension on the front of the building (illus 4).

It is thus demonstrable that the burials predate the construction of the existing building in 1821. The illustration of Lady Yester's Kirk on Edgar's map of 1742 shows clearly that the church was set well back from the line of Infirmery Street, and the burials excavated in 1993 can be securely identified as being from the kirkyard which surrounded it (illus 3).

#### *The burials (illus 6)*

All six inhumations were supine, with the head to the west, in conventional Christian arrangement. They generally respected the positions of other graves, and were buried in roughly parallel rows. Only the grave of SK 025 cut through earlier inhumations (SK 022 & SK 026). SK 022 had been extensively disturbed subsequent to interment. It is clear from the areas which contained no burials that there was no great density of burial during the use of the kirkyard.

There was evidence for the use of coffins from several graves. In Burial 001 nails, fragments of wood and the coffin stain survived. Burial 019 had a void above the remains and lines of nails along each side of the



ILLUS 6 13 Infirmary Street: burials in Area A

grave cut. Nails were recovered from within the grave fills of SK 022, SK 025 and SK 028, all closely associated with the bones. Nails associated with SK 026 had mineralized wood attached. Two badly corroded curved iron handles were recovered. One, approximately 40% complete, was associated with SK 028. The other, 95% complete, was found among a group of disarticulated bones. Both were most probably coffin handles.

The use of shrouds was attested by the presence of copper alloy pins close to the bones of SK 001, SK 025 (where they were attached to a small mat of hair) and SK 028. The finger bones of SK 028 were stacked vertically by the side of the body, indicating a tight binding of the corpse. Pins were also found associated with SK 026. These are discussed below in 'Post-mortem dissection'.

EXCAVATION RESULTS: AREA B (ILLUS 3)

A trench 1.3 m by 5.7 m by 1.2 m deep was excavated in the plant room at the rear of the building, which revealed the sleeper wall for the modern floor joists. Either side of this, and secondary to its construction, was dumped rubble which contained disarticulated human bone. As all this material

derived from obviously secondary or redeposited contexts, this collection of bones is considered as a single assemblage with that from Area A.

#### THE SKELETAL REMAINS

David Henderson

Stature has been calculated using Brothwell (1981, 101). Skeletons were sexed on the basis of pelvis and/or skull morphology, while certain of the unarticulated bones were sexed on the basis of measurements of articular ends (after Chamberlain 1994, 11). Broad age categories were determined on the basis of epiphyseal fusion and dental attrition (adapted from Brothwell 1981, 72). The minimum number of individuals represented within the assemblage was 14. All but one over approximately 17 years of age, the only exception being a child represented by a single distal diaphysis of a radius. Three were sub-adults (less than 25 years old, one was a young adult (25–35), and six were of middle age (35–55). Three were adult but of unattributable age. Four were definitely female, four male (and one other was possibly male).

For the *in situ* inhumations the following information was derived :

- SK 001 : female, 18–20 years, 1.68 m
- SK 019 : male, adult, 1.74 m
- SK 022 : male, middle-aged, 1.71 m
- SK 025 : female, 20–22 years of age, 1.55 m
- SK 026 : female, young adult, 1.62 m
- SK 028 : female, middle-aged, 1.59 m

#### *Pathology and non-metrical data*

Both skulls of SK 001 and SK 025 were scaphocephalic, ie the sagittal suture had closed prematurely. The absence of ‘keeling’ for both skulls despite the skeletal evidence that both were between 18 and 22 years old suggests that this process had occurred rapidly after the skull had reached adult size. Early closure of sutures is possibly a family trait, and the two individuals could be related (Molleson & Cox 1993, 129). They were buried adjacent to each other.

SK 028 displayed clear signs of DISH (diffuse idiopathic skeletal hypertrophy), and SK 022 had indicators suggesting the same condition. SK 028 also had considerable thinning of the centre of the blade of the left ilium, possibly due to osteoporosis (many of the articular surfaces were thin and slightly pitted). The neural arch of the fifth lumbar vertebra of SK 026 was detached (spondylolysis). Of the other pathological traces, the most interesting was a disarticulated right fibula shaft where the proximal end had been sawn off (see post-mortem section below). Periostitis discernible in the lower part of the shaft was perhaps evidence of the reason for the amputation. If the flesh of the lower leg was infected, probably with gangrene, the underlying periosteum would become inflamed, laying down the small quantities of bone characteristic of periostitis. Seven leg bones in total showed periostitis, mostly at the lower shin. This appears to be a very common site for periostitis in bones from medieval and later sites, probably reflecting overlying lesions. It is interesting that ‘sores on the leg’ was the third most common reason for admission to the Royal Infirmary in the 18th Century, after venereal disease and ‘fever’ (Risse 1986, 120). The low amputation rate and the very fact that so many cases were admitted would seem to indicate that Enlightenment medicine offered a high likelihood of effective treatment.



### *Post-mortem dissection*

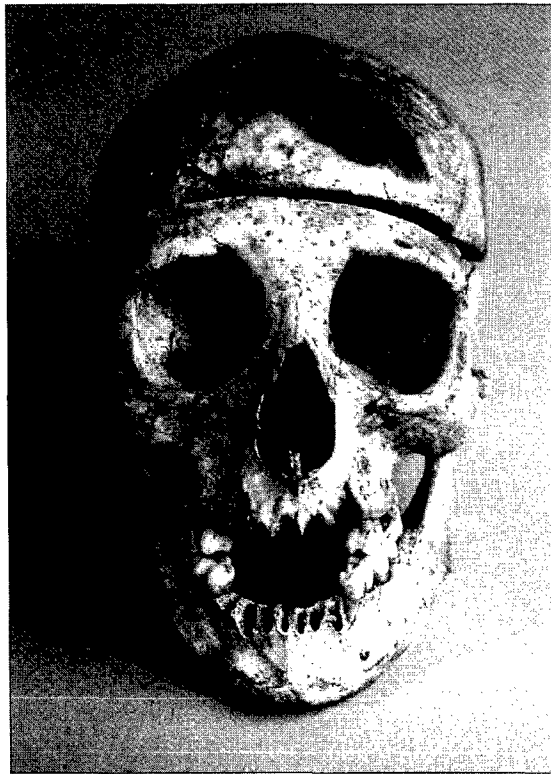Several of the inhumations showed evidence of post-mortem dissection. The most striking was SK 026. The cranial vault of this young adult female had been opened to examine the brain and meninges. The skull had been sectioned horizontally by saw at about 10 mm above the superior border of the orbit and just clipping the squamous suture (illus 7). Hair and scalp fragments found adhering to a pin on the front of the skull shows that her skin, which would have been cut sagittally and reflected down over her ears to section the skull, had been replaced over the repositioned calvaria (skull-cap). The presence of green copper alloy staining along the right side, as well as on the front of the skull-cap may indicate that the skin was simply pinned – rather than sewn – back into place prior to burial. There was also evidence that the tissues at the front of her legs had been opened. Her right femur showed possible paring marks on the anterior surface of the top third of the shaft, while her left tibia had a scalpel cut on its tuberosity.

SK 028 had scalpel cuts on the ends of the clavicles and adjacent parts of the manubrium sterni, probably evidence for examination of the thyroid gland, or the aortic arch. The entire thorax does not seem to have been opened. In excavation it seemed that left clavicle was still attached to the sternum and the right was pulled away, while the ribs were uncut. Cuts and nicks at the margin of the popliteal fossa on the left femur of the same skeleton are more difficult to explain – the thigh or the hollow of the knee may have been the site of some lesion, or a disease process associated with the cause of death.

Several of the disarticulated bones also displayed signs of post-mortem activity – one ulna had possible cuts on its interosseus surface, another had scrape marks at the origin of extensor indicis and at the median edge of the origin of flexor digitorum profundis. The other dissected bones were a distal half of an infant's radius with cuts on the posterior surface, a clavicle with scalpel marks on the posterior surface of the sternal half, a tibia midshaft fragment, quite abraded, but with signs of dissection and the fibula referred to above with the proximal end sawn off and extensive scraping along the interosseus border to separate it from the tibia.

### *Post-mortem tooth removal*

There was evidence for post-mortem mutilation (in the form of a more or less successful attempt to remove the front teeth) of each of the eight complete or partial dentitions recovered from the *in situ* inhumations and the disarticulated remains. There was an almost complete absence of incisors and canines from the site, and in five cases first premolars had been removed. In every case the thin bone on the buccal side of the alveoli was broken, particularly noticeable in front of the deep roots of the canines. In some cases the bone of the mandible and maxilla in front of these teeth can be naturally very thin and is often found broken in archaeological contexts. However, in many of the examples here what remains of the bone looks relatively strong. The complete absence of loose incisors or canines from any of the grave fills also suggests the pre-burial removal of the teeth. That the removal of these teeth was deliberate is shown by the presence of cut marks at the front of the canine alveoli of one of the disarticulated mandibles recovered from Area B. The alveolar bone was quite strong and the second right incisor had snapped, leaving a fragment of root *in situ*. Consequently it would appear that the bone by the canines was cut away to facilitate extraction. There was also evidence for variable levels of technical proficiency in the extraction process. In SK 001 the upper right second incisor and in SK 022 the lower right incisors and lower left canine were snapped off at the neck (in the case of SK 001 the adjacent canine was left *in situ*). Evidently a technique for dealing with unexpectedly strong roots was lacking.



ILLUS 7 Skeleton 026, showing the sectioned skull, evulsed teeth, and a stain on the forehead where some hair has been preserved around a shroud pin

### *Dental health*

A limited amount of information on dental health was derived, because of the removal of so many teeth from the skeletons. SK 001 had caries cavities, two rotten roots and large apical abscesses in both upper second premolars and both upper third molars were 'pegs', a congenital trait. SK 022 displayed periodontal disease with gumline retreat, while SK 026 had caries and possible developmental hypoplasia. In SK 025 the right upper deciduous canine (or 'milktooth') had been retained (although it was removed post-mortem) while its permanent canine was unerupted and twisted within the maxilla. Consequently the upper premolar was rotated and the third upper molar impacted. SK 028 had no third molars and had gross caries of the upper first molar. Of the disarticulated remains, one mandible showed a large apical abscess (possibly a tumour) and a double-rooted left canine and a second mandible had a large healing apical abscess.

### DISCUSSION

Mark Collard & David Henderson

Normally such a small total sample of post-medieval human bone would not be of any great significance, but in this case a number of interesting inferences may be drawn about the post-mortem fate

of the individuals concerned. Lying as they do within the burial ground used by the Royal Infirmary from 1749, and bearing marks of post-mortem dissection, they are almost certainly derived from patients who died while undergoing treatment at the Royal Infirmary in the latter half of the 18th century. It was hoped that the relative wealth of documentary material for this period of the Royal Infirmary's history would possibly allow the identification of individual cases. However, despite consultation of all bodies who hold archives of the Royal Infirmary, this has not, unfortunately, proved possible.

Between 1760 and 1800 a total of 2809 patients were recorded as 'dead' in the Royal Infirmary General Register (Risse 1986, 46–9). This represents a low average yearly mortality rate of 4.6%, although the mortality figures were deliberately managed to present the Royal Infirmary in the best possible light, for example by sending terminally ill patients home to die (*ibid.*, 289–91). Of those patients who did die in the care of the Royal Infirmary the vast majority would have been reclaimed by relatives for burial, or, in the case of soldiers, returned to the Army for military burial. It is possible that the individuals buried in Lady Yester's Kirkyard were those without relatives or those at a great distance from home. In all cases where a patient died, it was possible for the attending physician or surgeon to request permission to perform an autopsy. Strict procedures had to be followed before permission was granted. The signatures of three friends or relatives of the deceased had to be obtained, as well as those of three hospital managers, and the dissection had to take place in the third-floor teaching theatre of the Royal Infirmary (*ibid.*, 261). The popular horror of 'corpse mutilation' necessitated these rules and, indeed, permission was forthcoming for less than half the requests. Low hospital mortality meant that during the late 18th century only 15–30 autopsies a year would have been performed (*ibid.*, 264). In view of these constraints it is not difficult to imagine that the 'unclaimed' dead of the Royal Infirmary, with no relatives to object, would be a welcome source of material for surgical autopsies. In such cases the signatures of three hospital managers only were required.

It seems that the autopsy itself may often have been a relatively perfunctory affair, the physicians seeking merely to confirm their preconceived diagnoses, and the surgeons to examine their handiwork (although the latter seem to have been more eager to learn from their failures (*ibid.*, 262)). Teaching dissections for the benefit of students were not allowed at the Royal Infirmary. After dissection, the hospital insisted that the bodies be sewn up, dressed and returned, when appropriate, to the relatives for burial. Again, the good name of the Royal Infirmary depended on no charge of 'mutilation' being levelled.

The evidence of autopsy from these burials fits well within this framework. Limited areas of the body have been opened and examined, and in the case of SK 026 the appearance of the corpse was repaired. In view of this, it is notable that there was evidence for post-mortem mutilation of each of the eight complete or partial dentitions recovered. It is most likely that the teeth were removed by the person who shrouded the body in preparation for burial, after the dissection and repair by the surgeon or surgical clerk. It seems likely that this functionary would have been the hospital porter, possibly in conjunction with one of the nurses or washerwomen, and the likeliest motive for the removal of the cadaver's teeth is profit. Both nurses and porters were poorly paid and open to corruption (*ibid.*, 79). In the late 18th century there was a growing fashion for dentures, made of real human teeth and in some cases transplants were even attempted. Teeth secretly obtained from the corpses from the Royal Infirmary would have represented a good, if occasional, source of extra income – 19th-century resurrectionists could net £20–£30 for the teeth found in a single burial vault (Woodforde 1968, 62).

The relatively high proportion of dissected bones within the assemblage, including an unequivocally amputated fibula, is notable, and it may indicate that a certain amount of what would now-

adays be termed 'clinical waste', such as amputated body parts, was interred in the graveyard as the opportunity arose.

### SURGEONS' SQUARE, 1988

In 1988 a small assemblage of 63 items of bone was recovered by workmen during the removal of accumulated deposits inside the Flodden Wall (illus 1 & 2) at the Pleasance (NGR: NT 2623 7352). Of these, 12 were faunal, including five bones from the skeleton of an immature brown bear (*Ursus arctos*) and one apparently from an immature seal. Of the 55 bones identified, 47 (85.4%) were human, representing a minimum of five individuals (from pairing of tibiae) including a child of six to eight years old. Thirteen bones articulate to form two feet, and these have been counted as two separate items. On that basis, 37% of the recovered bones show evidence of dissection (13 bones) and 34% (12 bones) show pathological lesions, of which 58% (7 bones) had been dissected also.

Of particular interest are a left tibia and two vertebrae (thoracic 12 and lumbar 3) with abscesses of tubercular origin, a left humerus with severe osteomyelitis, and a right femur mid-shaft section with Paget's Disease where the distal end seems to have suffered trauma, either a fracture (spontaneous fractures are common in Paget's) or a surgical amputation. In the last example the bone end has undergone considerable healing, which has obscured the nature of the initial trauma. The posterior edges of the break show some eburnation which may represent either the ends of the bones rubbing against one another in an un-united fracture, or be the result of an ill-fitting prosthesis after surgical amputation. A left tibia distal end, with a united fibula had been sawn off and then sectioned coronally to demonstrate the ossified transverse and anterior tibiofibular ligaments.

The sectioned bones, the high levels of severe pathological lesions, the presence of an iron or steel pin inserted into the side of the tubercular lumbar vertebra and the exotic nature of the faunal remains, all suggest that these bones may derive from the demonstration specimens of an anatomy school. The site at which they were found was in the area north-east of Surgeons' Hall, built by 1697, which subsequently formed the heart of a medical quarter. The Royal Infirmary lay to the west and, by the time of Kirkwood's map of 1817, the garden north of Surgeons' Hall had become Surgeons' Square. Buildings on the east and west sides were occupied until the mid-19th century by private surgical and anatomical schools, including that of Dr Knox, who was infamously associated with the 'grave-robbers' Burke and Hare. The area excavated in 1988 lay immediately behind the east range of these buildings and they would seem to be the likeliest source for the bones, perhaps discarded when the University of Edinburgh occupied the area in the 1850s.

### ACKNOWLEDGEMENTS

Thanks are due to John Lawson, the staff of the Buildings Office of the University of Edinburgh, Kevin Wilbraham of the Edinburgh City Archives, Dr Mike Barfoot of the Medical Archive Section of Edinburgh University Library, Professor Kaufman of the Department of Anatomy of Edinburgh University, Professor Dugald Gardner and Dr Geissler of the Museum of the Royal College of Surgeons of Edinburgh, Ian Milne, Librarian of the Royal College of Physicians, Edinburgh, and Nicholas Holmes for information on the Surgeons' Square discovery.

## REFERENCES

- Brothwell, D R 1981 *Digging Up Bones* (3rd edn). London/Oxford.
- Chamberlain, A 1994 *Human Remains*. London.
- Cowan, W 1912 'The site of the Black Friars monastery from the Reformation to the present day', *Book of the Old Edinburgh Club* V (1912), 67–93.
- Edgar, William 1765 : *Plan of the City and Castle of Edinburgh*. National Library of Scotland EMS.s.55c.
- Gifford, J, McWilliam, C & Walker, D 1984 *The Buildings of Scotland : Edinburgh*. Harmondsworth.
- Kirkwood, Robert 1817 : *Plan of the City of Edinburgh and its Environs containing all the recent and intended improvements*. National Library of Scotland EMS.s.264,
- Molleson T & Cox M 1993 *The Spitalfields Project, Vol 2 : The middling sort* (= CBA Res Rep. 86).
- Risse, G B 1986 *Hospital Life in Enlightenment Scotland*. Cambridge.
- Woodforde, J 1968 *The Strange Story of False Teeth*. London.