

Excavation of a medieval cemetery at Holyrood Abbey, Edinburgh

Susan Bain*

with contributions by J D Bateson, J Clark, C Hazel, T O'Sullivan & R S Will

ABSTRACT

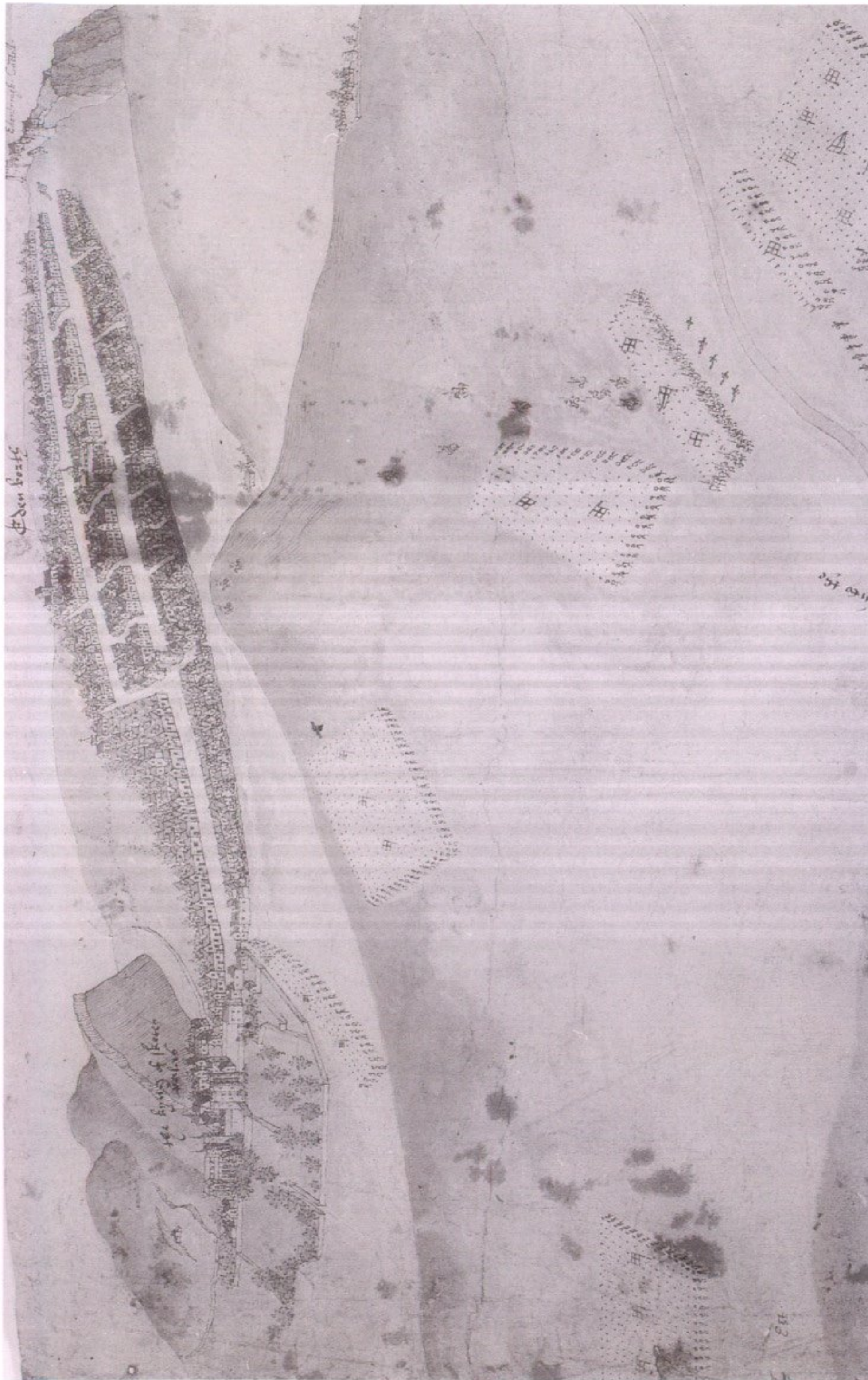A small archaeological excavation was undertaken at Holyrood Abbey in the spring of 1995 when human remains were uncovered by construction work to the west of the Abbey church. These formed part of the medieval cemetery and can be dated to the 14th/15th century. A ditch pre-dating the cemetery may represent an early boundary to the Abbey precinct. Building debris, including glass and window cames, is attributed to damage incurred during an attack by English forces in 1322. The project was initiated and funded by Historic Scotland.

INTRODUCTION

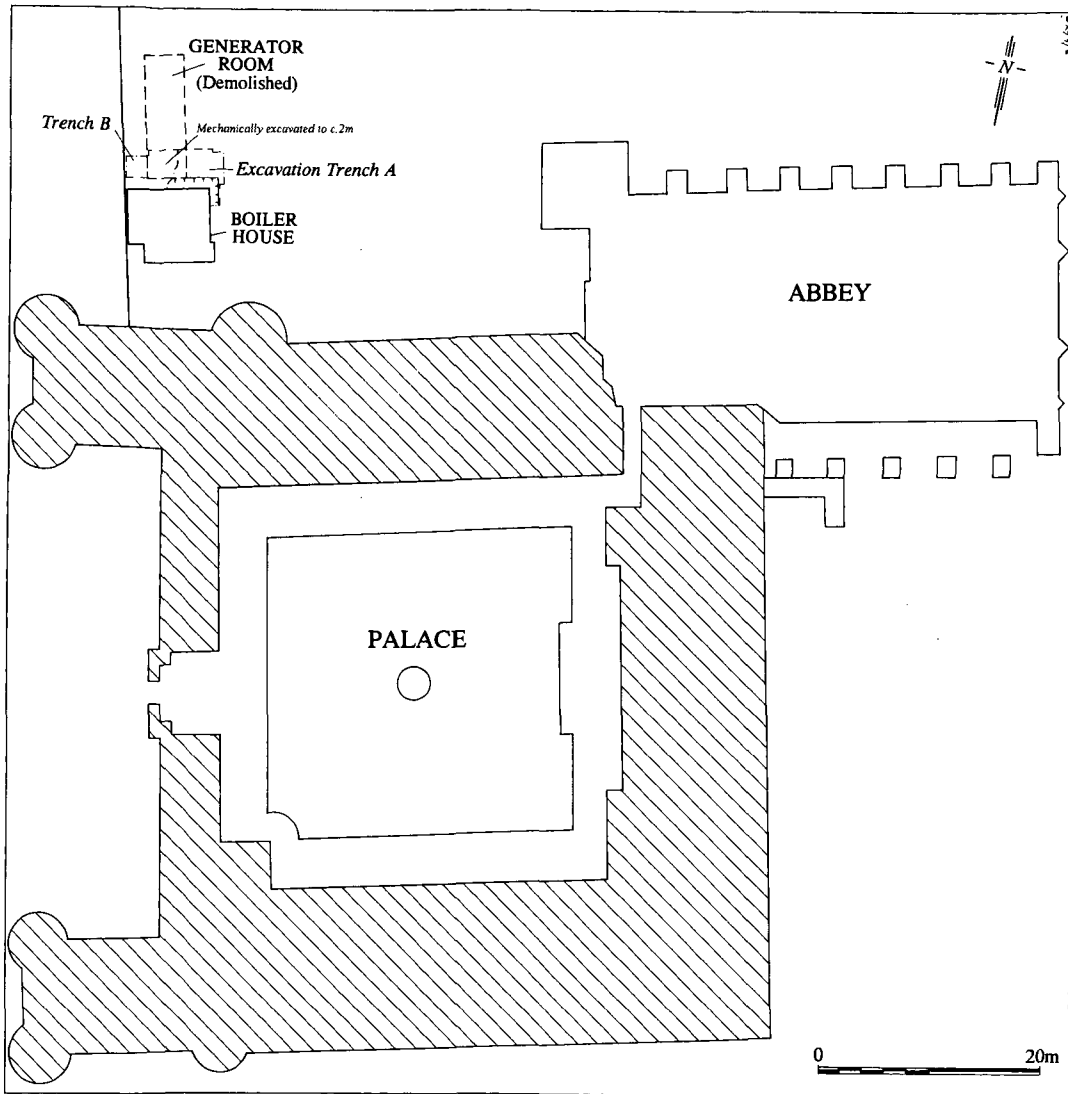
Holyrood Abbey and the Palace of Holyroodhouse lie at the eastern end of the long ridge of glacially deposited material which extends from the craggy hill occupied by Edinburgh Castle in the west, to the foot of Arthur's Seat and Salisbury Crags, in the east (illus 1). The upper reach of this ridge carried the medieval High Street and, below that, Canongate. Today all that is visible of the Abbey are the ruined nave and the foundations of the choir, transepts and part of the octagonal chapter house. These remains of the Abbey are dominated by the later medieval royal Palace of Holyroodhouse, which has incorporated the south-west tower of the Abbey church (illus 2). The immediate environs of these buildings are now gardens and, beyond that, royal parkland.

The Abbey was endowed by David I in 1128 and was one of several Augustinian houses founded in Scotland in the 12th century. From its foundation, the history of the Abbey was closely tied to the affairs of the royal houses of Scotland. This made the Abbey wealthy and influential, and the abbots sometimes held important political posts (Archibald Crawford, for instance, was appointed Lord High Treasurer in 1474), but it also meant that the Abbey was a prime target of invading English armies. During the Wars of Independence Holyrood was saved from the excesses suffered by some other Scottish religious houses by siding with the English. In 1296 Edward I resided at Holyrood where Abbot Adam swore allegiance to him in order to ensure the return of Abbey lands which had been seized (Bryce 1914, 13). However, Fordun reports that in 1322 the army of Edward II 'sacked and plundered the monasteries of Holyrood

* Glasgow University Archaeological Research Division (GUARD), Gregory Building, University of Glasgow, Glasgow G12 8QQ



ILLUS 1 The 'English Spy's' view of Edinburgh from the north, c 1544, with the burgh of Canongate extending west from Holyrood, on the left (*British Library Mss Cotton Augustus I, vol ii, ant 56*)



ILLUS 2 Site location within the environs of Holyrood Abbey. (Based upon the Ordnance Survey map © Crown copyright)

in Edinburgh and Melrose, and brought them to great desolation' (Harrison 1919, 11). The damage seems to have been quickly repaired, for five years later Robert Bruce held a parliament at Holyrood. The Abbey probably suffered minor damage during subsequent English incursions in 1355 and 1385.

In the 15th century Holyrood became a favoured royal residence and burial place. James II was born there in 1430, crowned there seven years later, and married at Holyrood in 1449. Initially, one of the several guest houses of the Abbey was probably reserved for royal use, as indicated by an entry in the Treasurer's Accounts of 1473 for 'ane glaswright in the Abbey for a window in the Quenis chalmire' (Harrison 1919, 15). But from the early 16th century, extensive

building programmes by James IV, and later by James V began to create the extensive Palace of Holyroodhouse which remains a royal residence today.

The neighbouring burgh of Canongate was granted to the Abbey shortly after its foundation. The nave of the Abbey served as a parish church for Canongate, and a yard on the north side of the church became the parish burial ground (see Gallagher, this vol, illus 4).

The Abbey was looted and burned twice in the 1540s by the Earl of Hertford's troops, during the 'Rough Wooing' of Henry VIII. The ruinous choir and transepts were eventually demolished in 1570, leaving only the nave to serve as the parish church. Restoration and improvements were carried out in 1633 for the coronation of Charles I and the nave became a richly decorated chapel royal. It was adapted to this role again in 1687 as a Catholic chapel for James VII. In 1758 the nave was re-roofed, replacing a timbered structure with stone flags. This proved a disastrous decision; the weight of the roof was too much for the underlying structure and the vaulting collapsed. Since then the church has remained a ruin.

A more detailed account of the history and especially the development of the Abbey is given by Gallagher (this vol).

PREVIOUS ARCHAEOLOGICAL EXCAVATIONS

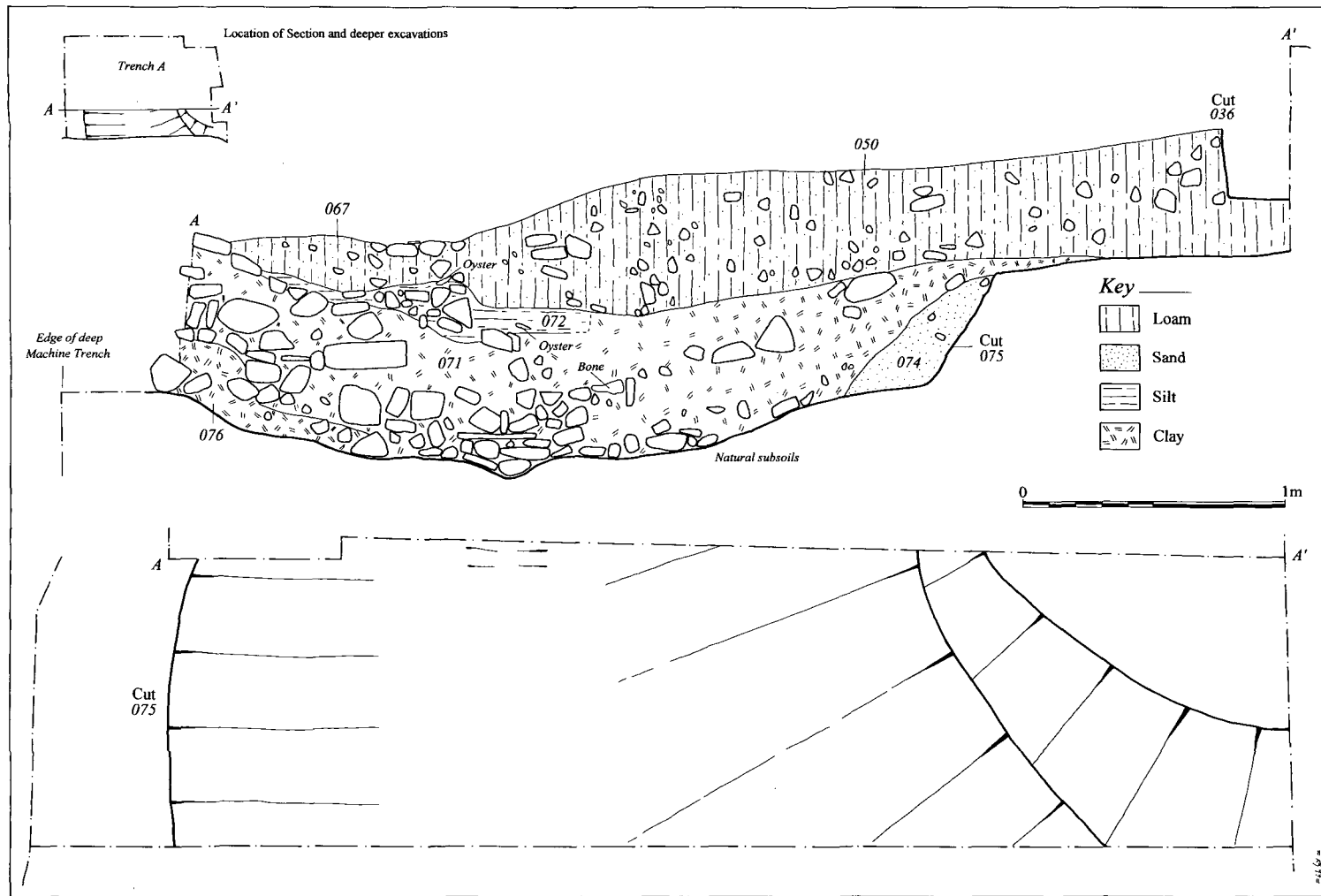
The only previous excavations were carried out in 1911 and 1924 by HM Office of Works in the course of clearance and consolidation works (Oldrieve 1912, 329). These revealed the footings of the 13th-century choir and transepts which had been demolished in 1570, but also foundations of an earlier building, probably the primary 12th-century church of the Abbey. About 25 burials were exposed to the south and east of the church. These were probably medieval in date and some appeared to have been disturbed by the construction of the 12th-century church.

EXCAVATION IN 1995

This excavation was commissioned by Historic Scotland when human remains were exposed by construction of a stairwell leading to a sunken Victorian boilerhouse in the area west of the Abbey church and north of the Palace (illus 2). An existing generator room was demolished prior to the start of archaeological work; then topsoil was removed under archaeological supervision by a JCB using a smooth-edged ditching bucket. The area excavated was confined to 2 m by 4.5 m, being the area required to construct the stairwell. Burials exposed outwith this area were also recorded, but only the uppermost remains were removed, to prevent possible damage. During the excavation temperatures frequently dipped below freezing. Frost damage to the exposed bone was a problem, despite covering the site with plastic sheeting when work was not in progress. Burials, once exposed, were excavated as quickly as possible to prevent frost damage, but also to minimize their exposure to the public gaze.

SUMMARY OF THE EXCAVATION RESULTS

Six phases were identified in the archaeological record. The earliest element is a large pit or ditch, possibly a primary precinct boundary to the Abbey (Phase 1). This was backfilled with a variety of materials including soil and rubble (Phase 2); these fills contained some midden material and also disturbed human remains. At some subsequent point, building debris, including broken window glass and lead comes, was spread across the site, obviously resulting from damage to the Abbey (Phase 3). Numerous burials, crowded and intercutting, were subsequently cut through



ILLUS 3 Plan and section of the possible early boundary ditch (Phase 1-2).

this layer (Phase 4); at least 51 individuals were present. After burials stopped in this area, foundations of a 17th-century building — one of the royal apartments — were cut into the cemetery, truncating some graves (Phase 5). Finally, some time after this building was demolished in the early 19th century, the boilerhouse and a generator room were constructed and the area landscaped as a garden (Phase 6).

PHASE 1: EARLY BOUNDARY DITCH (ILLUS 3 & 4)

The earliest excavated feature was a large flat-bottomed pit or ditch (75). Unfortunately, within the limited area of excavation neither the extent nor shape of the feature were revealed. Furthermore, the feature was truncated by 17th-century foundations to the west (Phase 5) and by the construction of the boilerhouse to the south (Phase 6). A slot trench (1 m wide by 4.5 m long) revealed that the feature was up to 1 m deep and filled by mixed soil and rubble, containing midden material and also some disturbed human bones (illus 3).

The interpretation of this feature is problematic given that its extent and shape remain unknown. A pot sherd of Yorkshire type fabric within the lowest fill (74) provides a *terminus post quem* of c 1250 for this deposit. The pottery from the remaining fills includes Scottish East Coast White Gritty Wares and Yorkshire type fabrics, both of 13th/14th-century date (see Will, below). Thus, the feature itself probably pre-dates the 13th century. If it was indeed a ditch then it may have formed the western boundary of the Abbey precinct. Drawings by Gordon of Rothiemay (Gallagher, this vol, illus 2) and Captain John Slezer (Cavers 1993, 99) both show some type of boundary, either a wall or hedge, traversing this area from north to south in the 17th century. Indeed, at present, a wrought-iron fence and hedge lie along this same line. These later boundaries run approximately 2 m west of the excavated feature and could perpetuate a more ancient line.

However, on the available archaeological evidence, this feature may equally well be interpreted as a pit, dug perhaps to quarry the natural clays which occur in the area and then backfilled with rubbish from the Abbey.

PHASE 2: DITCH FILLS AND LEVELLING DUMPS (ILLUS 3)

The large pit or ditch described above was backfilled with mixed clays, silts, sandy loams and rubble. These fills contained large amounts of unworked stone and also one slab of roughly worked sandstone; there was mortar in the uppermost fill (67). The most likely source of this material would be the immediate area of the Abbey, which would have been a hive of building activity in the 13th century, involving not only construction work, but also perhaps the demolition of earlier structures.

The fills also contained some midden material, including animal bone, oyster shell, pottery sherds and charcoal. Indeed, most of the faunal remains recovered by the excavation were from amongst these fills. These consisted mainly of butchered remains of cattle and sheep, but also included horse, roe deer, pig and domestic fowl. In fact, horse bone was recovered only from the fills of this feature and did not appear anywhere else on site. Butchered horse bone has been noted at other medieval sites in Scotland, and may have been consumed by humans during periods of extreme food shortage. Alternatively, as the horse bones did not display as many butchery marks as sheep and cattle bones, they may simply have been dismembered for easier disposal (see O'Sullivan, below).

Two of the fills (67 & 74) contained disarticulated human bone, including vertebrae, skull and long bone fragments. It is possible that these are simply disturbed remains from the earliest

use of the adjacent parish burial ground, in the north yard of the Abbey; alternatively, they may represent disturbed burials associated with an earlier, unrecorded church.

These lower, mixed fills were sealed by a deep layer of brown sandy loam (50; with upper variations 3 & 13) which overspread the top of the ditch; this was flecked with mortar and charcoal, and also contained animal bone, pot sherds and fragments of window glass and lead comes (see Phase 3, below). In the first half of the 13th century, Abbot Elias was responsible for draining the area around the Abbey and 'enclosed a cemetery with a stone wall' (Maxwell 1934, 72). Thus, this deep soil layer may represent deliberate levelling as part of a programme of general landscaping, which included drainage and construction of new enclosure walls.

PHASE 3: ENGLISH ASSAULTS

The levelling layer described above (50) produced most of the glass fragments and lead comes recovered from the site, as well as one architectural fragment (not illus) and a small fragment of gilded plaster (not illus). These inclusions represent damage to the fabric of the Abbey, but when did this occur? All of this material was disturbed and redeposited to some degree, as later (Phase 4) burials were cut through the soil layers in which they occurred. Nonetheless, the date of primary deposition can at least be estimated from the available stratigraphic and artefactual evidence. The backfilled ditch contained 13th/14th-century pottery (Phase 2); furthermore, burials in this area — which probably ceased soon after 1500 — are likely to have extended over several generations before this (Phase 4, below). Therefore the destruction for which we have evidence most probably occurred at some point in the 14th century.

Edward II's attack on the Abbey in 1322 caused 'great desolation' (Harrison 1919, 11); and minor damage was also suffered during further English incursions in 1355 and 1385. It is tempting to assign the destruction material to the events of 1322. Two coins were recovered from the soil layer over the ditch (13) and from a burial cut through this (38); both coins date from the early 14th century and one, an Edward I/II silver halfpenny, was probably deposited before 1350 (Bateson, below). Furthermore, the glass assemblage includes painted fragments of 12th- to 14th-century date (see Bain & Clark, below). A parliament was held at Holyrood in 1327, suggesting that the damage did not affect the entire Abbey complex. Perhaps the 'great desolation' was the looting of the Abbey treasury and desecration of costly windows and fine architectural details rather than serious structural damage. The construction of the Abbey was still incomplete in 1322 and a great many artisans would have been 'on-site'. One can imagine the scene after Edward's forces left, with masons and glaziers picking through the wreckage and salvaging their work as best they could.

PHASE 4: THE CEMETERY (ILLUS 4)

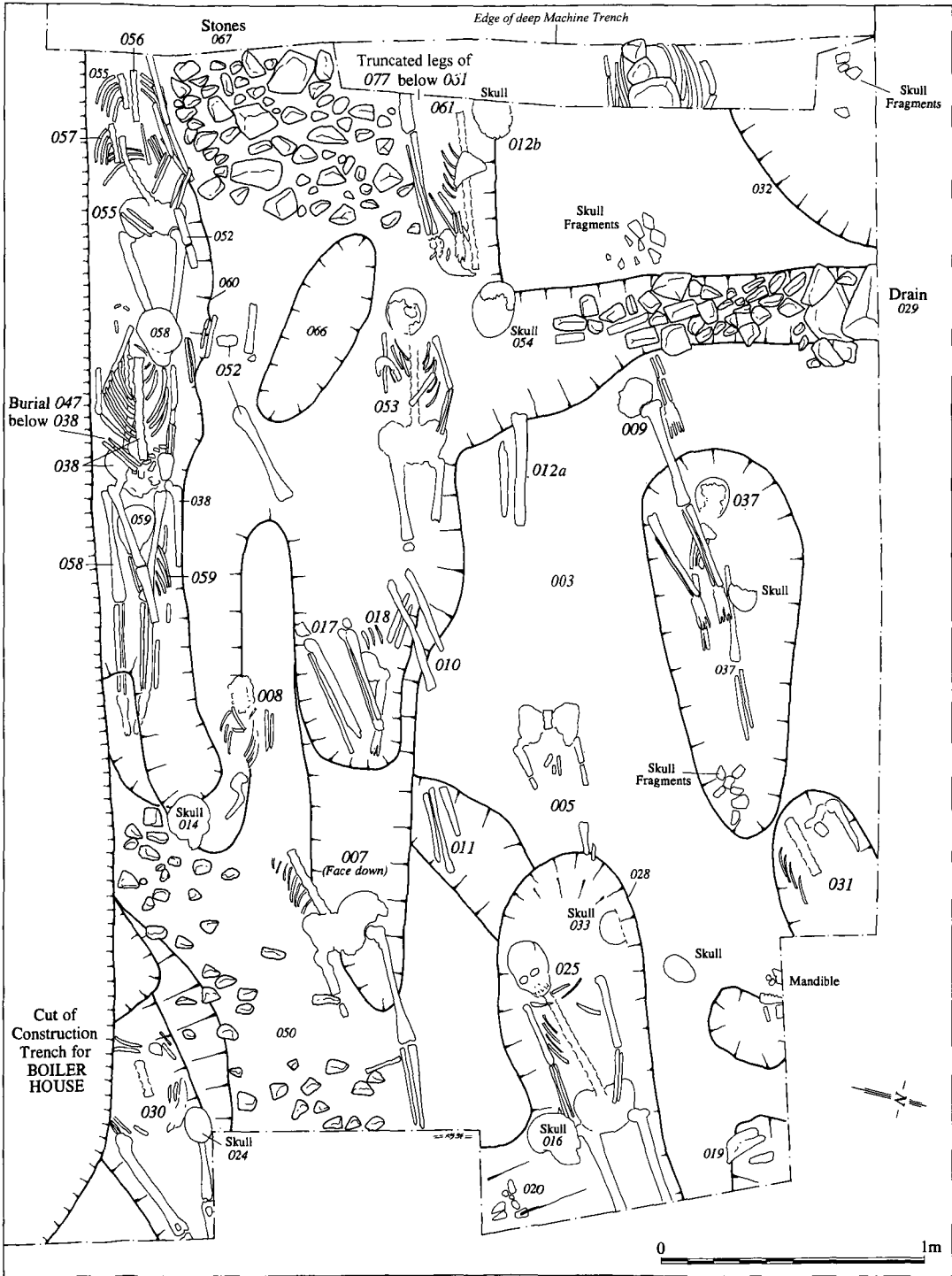
Skeletal remains of at least 51 individuals were identified within the excavated area, however, as the graves were crowded and intercutting, only four skeletons were largely complete (ie 80–100%). The remainder were represented by disturbed, incomplete skeletons or loose, disarticulated bones. As described above, the burials lay within an homogenous sandy loam soil layer (Phase 2), indicating heavy reworking of the soil and intensive use of the area as a burial ground. It is very likely that burials once extended beyond the trench on all sides; this could not be ascertained, however, as they were truncated to the west by the foundations of a 17th-century building (Phase 5) and to the south by the construction of the Victorian boilerhouse (Phase 6).

The burials were all extended, supine inhumations, except for one prone burial (Sk 7) and one infant lying on its side (Sk 59). Arms were either at the side or across the pelvis, though the incomplete nature of many burials does not preclude other positions. Only one individual, a year-old child (Sk 62), lay true east/west; the remaining graves were parallel to the main alignment of the Abbey church (ENE/WSW). The closely set remains of three burials (Sk 53, 58 & 59) suggest the limbs were tightly bound, perhaps within a shroud (ie coffined remains are more likely to lie a little apart within the grave once the flesh has decayed; the feet, for instance, are often splayed). No shroud pins were found, but the cloth could have been stitched or laced rather than pinned. Medieval burials were usually naked within the shroud, but there is evidence that some individuals at Holyrood were clothed. A silver penny (no 90, below) was found close by the hip (pocket?) of one individual (Sk 38) and an iron buckle (no 84) was found in the abdominal region of another (Sk 47). The presence of iron nails in the grave fills and a ferrous concretion on one femur suggest that at least three individuals (including Sk 47) were buried in coffins, rather than shrouds; two of these were infants (Sk 37 & 62).


Intercutting graves are typical of crowded medieval cemeteries; however, the remains of three individuals appear to have lain in a single grave, where they overlap rather than intercut (ie no evident damage to any of the three was caused by burial of the other two), suggesting that they were buried together. A young infant (Sk 59), under one year old, lay on its right side in a loosely flexed position, immediately under the left leg of an adolescent female (Sk 58), who in turn lay directly over the lower legs of an adult male (Sk 55). (The burial of children on their sides during the medieval period was noted in the Dominican cemetery in Perth (Bowler *et al* 1995, 943), where it is suggested that the practice reflects a 'sleeping' position.) This may have been a family group, all of whom died within a short period of time, though it is worth noting that there were no shared non-metric skeletal traits amongst this group, which might have confirmed this suggestion (see Hazel, below).

The inverted or prone position of one individual (Sk 7) is unusual, but has been recorded at other medieval cemeteries. It has been suggested (A Cardy, pers comm) that individuals buried this way may have been perceived as abnormal, because of a physical or mental disability, or perhaps were social outcasts. A prone individual from Whithorn displayed uneven disuse atrophy of the lower limb (Cardy 1997, 551) and another from the Bay of Skail, Orkney, may have suffered some form of mental disability (Lorimer, pers comm). However, there was no evidence of misadventure (trauma or disfiguring disease) on the skeleton at Holyrood which might have been responsible for this different treatment of the individual, and careless or clumsy burial could have been the explanation for its prone position.

The sample of human remains recovered from Holyrood is too small to support statistically significant conclusions about the demography of the population, however, some general points can be made (see Hazel, below). All age groups are represented and both sexes are present in equal number within the adult age groups. Thus, there is no evidence to suggest that this group represents either the convent of the Abbey or the royal household — where either a bias in sex or a higher age-at-death (reflecting higher status) might be expected — and it probably formed part of the parish cemetery of Canongate. Indeed, the excavated area lies at the western boundary of the large yard described as 'The Kirkyard' on the plan of Edinburgh made in 1647 by Gordon of Rothiemay (see Gallagher, this vol, illus 2). We may surmise that the inhabitants of Canongate included labourers and soldiers, farmers and butchers, artisans and merchants, as well as millers, scribes and bureaucrats. The present group is typical of Scottish urban medieval cemetery populations, reflecting the diversity of such a community.



ILLUS 4 Composite plan of Trench A (ie showing features from all phases)



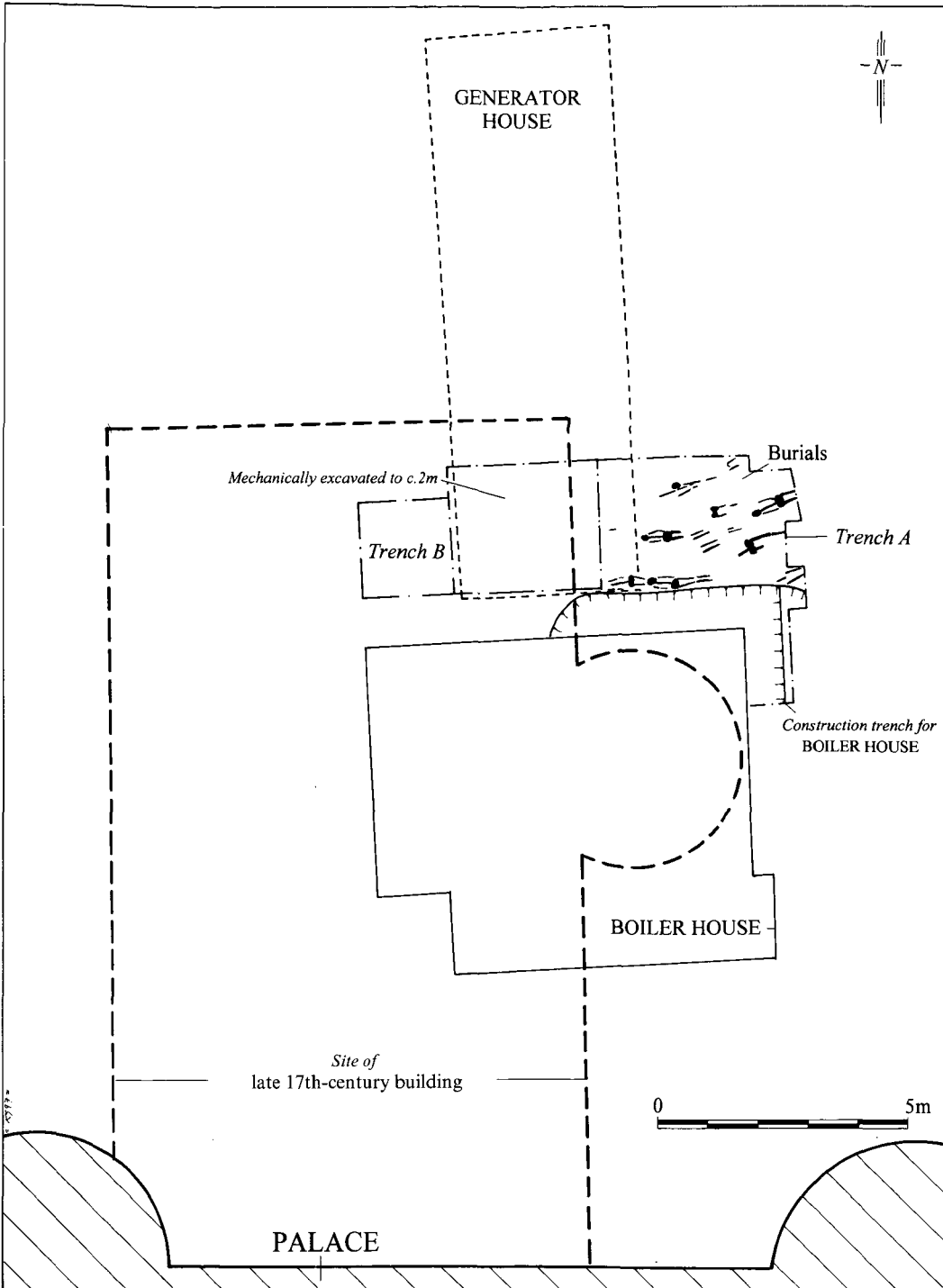
ILLUS 5 A view c 1826 of the extension to the royal apartments, built in 1676 (RCAHMS © Crown copyright)

PHASE 5: 17TH-CENTURY RANGE (ILLUS 5 & 6)

The burials were truncated to both the west and south. Construction of the upstanding Victorian boilerhouse was clearly the reason for the disturbance to the south, but there was no obvious explanation for truncation on the west. Here, the skulls of three individuals were missing (Sk 55, 56 & 61) and the legs of another (Sk 77) were neatly chopped off at the femora. This could not be attributed to modern construction work, as truncation of the burials took place at a level below the foundations of the former generator room; furthermore, an extension of the archaeological cutting on the west side (Area B) was excavated to a depth of 1.15 m, without discovering any surviving evidence for human burials. An alternative explanation for the absence of human remains on this side was sought.

Historical records show that a range of buildings existed in this area in the post-medieval period, abutting the great tower completed for James V in 1532. This later range appears in 17th-century plans by Gordon of Rothiemay and John Mylne (Gallagher, *this vol*, illus 2 & 3), and in an 18th-century plan by William Adam (not illus). In its earliest form it is described by Gallagher as a timber gallery, giving access between the royal apartments and gardens to the north, and bridging the public road from Canongate to the Abbey church (and presumably the parish cemetery); but this was demolished in 1676 and replaced with a stone building which formed part of the royal apartments (illus 5).

Although the parish cemetery was still in use in the post-medieval period, it must be considered unlikely that burials continued in the immediate area of the excavation after c 1500.



ILLUS 6 The 'footprint' of the late 17th-century building imposed on Trench A; after William Adam's 18th-century ground plan of the Palace of Holyroodhouse (RCAHMS © Crown copyright)

Certainly it would appear that this area was long out of use when the timber gallery was replaced by a stone building in the 1670s, for it appears that it truncated the burials on the west. By superimposing an outline of the building based on William Adam's plan on the excavated area (illus 6), it can be seen that the east wall of the new building fell approximately where the truncated burials were observed in the excavation. (No foundations or other material associated with this building were observed during the excavation, apart perhaps from a thin mortar-rich layer observed at a depth of 0.75 m in Trench B.)

PHASE 6: POST-MEDIEVAL ACTIVITY (ILLUS 4)

The building described above was eventually demolished in the mid 19th century. Victorian landscaping and construction of a boiler house would have contributed to its near total disappearance, leaving only the large foundation cut which was recorded by the present excavation. Other post-medieval features included a rubble drain (29) which ran north/south across the site and pits, by the east baulk, cut from the modern ground surface. Apart from stone and modern debris, one of these contained disarticulated human bone, including a skull with an unusual blade injury (see Hazel, below).

SPECIALISTS' REPORTS

Complete catalogues of all materials described by the following summary reports form part of a project archive deposited with the National Monuments Record of Scotland.


WINDOW GLASS

Susan Bain & Jane Clark

The excavation yielded 104 fragments of medieval window glass and many smaller particles. (This represents a substantial assemblage from a Scottish medieval site considering that the excavated area was only 4.5 m by 3 m.) Most of the glass is extremely fragmentary and in very poor condition. During the medieval period potash was used as a flux in glass production. Potash glass is prone to corrosion on contact with water and typically pits and cracks. The Holyrood glass exhibits many problems of corrosion and physical breakup. Most fragments have lost all transparency and have reacted to form a blackened corrosion product. The cross-sections of many fragments show that the sherd body is completely corroded throughout, not only on the surfaces. The enamel paint on window glass was normally a copper or iron oxide with a binding material, such as gum arabic, to give adherence to the glass. Lead was nearly always present in enamels, to lower the melting point and to increase stability and fluidity. The paint was applied, and then the glass was fired.

Little is known about glass manufacture in medieval Scotland. The earliest historical reference is the granting of patent to make glass in 1610 (Hurst-Vose 1988, 69). Prior to this it is assumed that glass was imported from England and abroad. The Rhineland, in particular, was a centre of coloured glass production and was exporting to northern England in the 13th and 14th centuries (Graves 1995, 110).

The extensive corrosion of the glass from Holyrood has meant that it was possible to identify the original colour of only two fragments: a fragment of flashed ruby (a method of making red glass where a thin layer of red glass is spread or 'flashed' over a layer of white glass)



ILLUS 7 Painted window glass. Scale 1:2

and a fragment of yellow glass. Three fragments have smooth rounded edges which indicate that the glass was manufactured using the cylinder or muff process, which results in flat sheets with a characteristic fire-rounded edge.

Applied decoration is visible on 37 fragments. The designs include foliage, trefoils and curvilinear or geometric patterns, with areas of cross-hatching infill. One fragment shows part of some drapery from a figure (illus 7, no 15). These designs are consistent with grisaille decoration and the presence of trefoil motifs, cross-hatching and stiff-leaf foliage suggest a broadly 12th- to 13th-century date, with some fragments also present from the 14th century.

Several fragments have grozed edges where an individual piece of glass — or ‘quarry’ — was trimmed to fit into an overall design and held in place with a H-shaped lead came. The fragmentary nature of the glass has resulted in only five quarry shapes being identified, two diamonds or triangles, and three rectangles.

It is difficult to assess the state of the glass at time of primary deposition, as further damage would have occurred as graves were dug and the soil turned. Also, any large glass fragments would have been salvaged and incorporated into new windows, or collected as cullet and remelted. Glass was too expensive in the Middle Ages not to be recycled and even as late as 1673 repairs to windows at the Palace of Holyroodhouse reused ‘130 feet of old glass and 311 feet of

new English glass' (Robertson 1860, 116). Similarly the lead comes could easily be melted and re-shaped to form new comes.

As described above, some of the stained and painted glass can be dated stylistically to the late 12th or 13th century and may represent glass from the first building programme, begun about 1190. All except two fragments came from the deep loam soil layer (Phase 2, 50) or from grave fills (Phase 4) cut through this layer. No glass was recovered from the earlier ditch fills (Phase 2). As the burials probably date from the mid 14th century onwards, the assault by Edward II's troops in 1322 would seem to be a likely context for such extensive damage to the windows of the Abbey.

Catalogue of illustrated examples (illus 7)

- 15 Two conjoining fragments, 73 mm by 48 mm by 4 mm. Drapery from a figure, 13th–14th century. Grozed on three edges forming a rectangular quarry. Context 50 (Phase 2).
- 16 One fragment, 39 mm by 40 mm by 3.8 mm. Trefoil design surrounded by cross-hatch. One grozed edge. Context 50 (Phase 2).
- 17 One fragment, 38 mm by 26 mm by 3 mm. Double stem/stalk. Context 50 (Phase 2).
- 27 One fragment, 77 mm by 34 mm by 5 mm. Smooth fire-rounded edge, indicating cylinder production. Context 50 (Phase 2).
- 29 One fragment, 40 mm by 28 mm by 3.2 mm. Probable diamond quarry with radiating line pattern, floral motif. Context 50 (Phase 2).
- 30 One fragment, 44 mm by 25 mm by 5 mm. Natural foliate design. Leaf in reserve, 13th–14th century. Context 50 (Phase 2).
- 31 One fragment, 32 mm by 20 mm by 3 mm. Trefoil with cross-hatch design, grozed on one edge. 13th century. Context 50 (Phase 2).
- 32 One fragment, 27 mm by 16 mm by 4 mm. Natural foliate design. Leaf in reserve, 13th–14th century. Context 50 (Phase 2).
- 33 One fragment, 27 mm by 20 mm by 2.9 mm. Cross-hatch decoration. Context 50 (Phase 2).
- 36 One fragment, 25 mm by 16 mm by 3.1 mm. Wide cross-hatch decoration, grozed edges. Possible triangular/ diamond quarry. Context 50 (Phase 2).
- 40 One fragment, 10 mm by 10 mm by 3.1 mm. Cross-hatch decoration within border. Context 50 (Phase 2).

METAL OBJECTS

Eighty-two metal objects were recovered during the excavation. The majority were of lead (40) or iron object (29); the remainder were of copper alloy (9) or of composite materials (4).

Lead (not illus)

The lead objects came primarily from layer 50 (Phase 2) or from grave fills cut into this. The largest identifiable group (19 fragments) was of window comes, and all but one of the other pieces may be related to the production of windows, or window comes. Most of the fragments were too twisted for a more detailed identification to be made. Five examples are made from cast lead with four having a prominent cast ridge. This technique represents the earliest technology; milled lead comes do not appear until sometime in the 15th century (Knight 1985, 154). Three fragments of came are for a junction, forming a triangular or diamond-shaped quarry. Several fragments of flat, thin, lead ribbon may simply be trimmings from came production. A thin cylinder with a

flattened end may also be residue from came production. Two small amorphous lumps of unworked lead suggest metalworking was conducted on or near the site, such as roofing.

As described above (see 'Window glass'), lead from broken windows does not occur frequently in archaeological deposits as it would most certainly have been recovered, where possible, for reuse. Although it is valuable it is also easy to work, and reuse of older material is a simple process.

Copper-alloy (not illus)

The copper-alloy objects included two pins, a lace end, one fragment of wire twisted into a bag tie, four unidentified fragments and a small finger ring. All of these were recovered from the deep soil layer overlying the ditch (Phase 2).

The pins may be shroud pins, but neither example was recovered from a grave context. Laces were used for fastening many articles of clothing, including jerkins, hose and jackets (Gabra-Sanders 1995, 88) but may also have been used as a shroud fastening; again, however, the lace end recovered was not in direct association with a burial.

The finger ring was the only piece of personal jewellery recovered from the excavation but was not associated with a burial. Jewellery is not common among medieval burials and the ring may have entered the archaeological record simply as an accidental loss.

81 **Finger ring** A ring formed on a plain band with a diamond cross-section. Diameter 16 mm. Context 50 (Phase 2).

Iron (not illus)

Twenty-nine iron objects were recovered from the excavations; all except one were iron nails. Most of the nails were from grave fills (Phase 3) or from the deep soil layer in which the graves were cut (Phase 2), where they may have been redeposited as graves were dug.

The location of six nails around the edge of one grave is highly suggestive of a coffin. The remaining iron object, a belt buckle, was recovered from the abdominal region of the skeleton within this grave (Sk 47); this indicates burial in clothing rather than a shroud, which usually involved removal of clothing.

84 **Buckle frame** Rectangular, double-hole design, of a common all-purpose type found throughout the medieval period in a variety of sizes. No pin. Context 48 (Phase 4).

COINS AND JETTONS

J Donald Bateson

A silver penny of Edward I (no 90) was recovered from one grave (Sk 38), where it appeared to be clasped in the left hand or perhaps in a pocket. The penny was minted in Berwick c 1300–10 but may have been in circulation in Scotland as late as 1380. An Edward I/II silver halfpenny (no 91) was recovered from the deep soil layer through which graves were cut (Phase 2); this was minted in London c 1301–35, and probably deposited before 1350. A copper reckoning counter or jetton (no 92) was minted in France in the 14th/15th century was also recovered from this context.

90 **England, Edward I silver penny**, Berwick; probably Class 4(b) (c 1300–10); fairly worn/clipped; 1.01 g (15.6 gr)/270, reverse reads VILL/ABE/RE9V0/VICI. Probably deposited by 1330, but such Edwardian pennies did circulate as late as 1380 in Scotland. With Sk 38 (Phase 4).

- 91 **England, Edward I/II, silver halfpenny**, London; Class 10–11 (1301–35); slightly worn, 057 g (8.8 gr)/30, reverse reads CIVI/TAS/LON/DON. Probably not very long in circulation and deposited before 1350. Context 13 (Phase 2).
- 92 **Reckoning counter or jetton**, French, 14/15th century; copper, slightly worn/1.07 g/20 mm. Obverse: large open crown with jewels of trefoil form + AVE MARIA GRACIA PLENA (two stops of two small crosses); reverse: double curved across fleury with lis in centre and rosette in angles + A/VE/M/AR (single cross before and after each quarter).

POTTERY AND CERAMIC TILES (ILLUS 8)

Robert S Will

The excavation produced a total of 83 ceramic sherds from 19 contexts. The sherds date from the medieval to modern period and include two tile fragments, as well as numerous pottery sherds. They were subjected to visual examination only; no fabric analysis was carried out. As this is a very small assemblage with the different pottery fabrics often represented by only one sherd, very little can be said about the shape, form or decoration of the vessels.

Decorated floor tiles

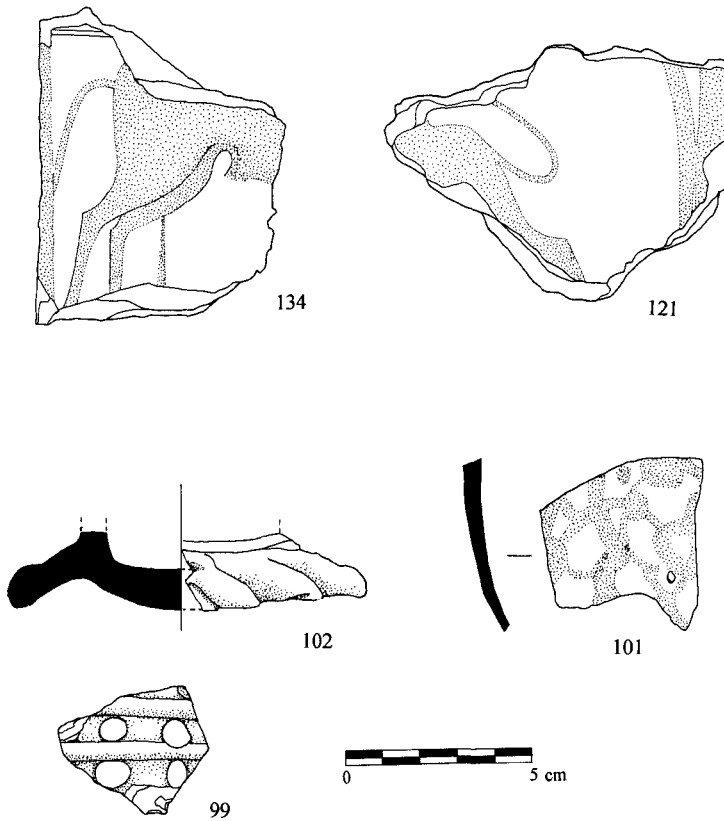
Fragments of two impressed decorated floor tiles were recovered (nos 121 & 134). The surviving design on both represented the back legs of an animal, possibly a horse or panther. The tiles were covered in a green glaze. Similarly decorated floor tiles were recovered from the Cistercian tile kiln at North Berwick Priory, where they are thought to date to the 13th century (Richardson 1929). Aliaga-Kelly & Proudfoot (1995) have noted the general rarity of medieval tiles in Scotland and of decorated floor tiles in particular. Imported floor tiles did, however, enjoy two periods of popularity in Scotland, in the 13th century and again in the 16th century.

Medieval wares

Scottish East Coast White Gritty Ware The largest fabric group (43 sherds) represents the local pottery industry of Fife, Lothian and the Borders. The earliest known group of this material was recovered from Kelso Abbey and dates to the later 12th century (Haggarty 1984, 397), but the industry continued into the 15th century (MacAskill 1982). On the whole, most of this ware dates to the 13th century. Two of the sherds are from cooking pots and have the characteristic sooting and fuming marks around the basal angle. Due to the small size of the sherds it was not possible to determine the shape of the vessels.

Scottish medieval redwares Three body sherds from partly glazed jugs were recovered. These fabrics generally date to the 14th and 15th centuries and are thought to have been produced at a number of kiln sites throughout Scotland in areas of iron-rich clays. At present, Rattray in Aberdeenshire is the only published kiln site (Murray & Murray 1993); here, production is thought to have been on a small scale to meet local demand.

Yorkshire wares A rim sherd and body sherd in Yorkshire type fabrics were recovered. Several kilns were operating in Yorkshire in the period 1250 to 1350. These produced a wide range of highly decorated jugs with mounted figures and animal motifs, as well as more everyday vessels with face-masks, ribbing, pellet decoration and combed or applied patterns. The rim sherd is from a jug and has a scar on the upper surface where the glaze had run, sticking to the vessel immediately above it in the kiln stack.



ILLUS 8 Sherds of pottery and decorated floor tiles. Scale 1:2

Humber Ware One body sherd of Humber Ware was recovered. Similar fabrics were made at a number of kilns, including West Cowick, from c 1250 to 1450. The vessel forms are similar to those from the Yorkshire kilns, usually decorated jugs with a dark green glaze (McCarthy & Brooks 1988, 247). The sherd from Holyrood has a reduced grey/black fabric and a dark green glaze.

Scottish post-medieval reduced ware

This fabric type is found throughout Scotland and remained in use for a long period of time, from the 15th to early 18th centuries. One body sherd was recovered at Holyrood. A kiln site has been excavated at Throsk, on the upper Forth near Stirling (Caldwell & Dean 1992). The vessels tend to be large jugs with simple rims and strap handles and usually have a thick green glaze decorated with incised wavy lines, especially around the shoulders (Haggarty 1980, 40).

Imported pottery

Andalusian Lustreware Two body sherds from a flask or vase with simple blue decoration were recovered (no 101). Andalusian Lustreware was made around Malaga and Seville and is divided into two periods: 'Early Andalusian' (13th–15th century) and 'Late Andalusian' (up to the 16th century) (Gerrard *et al* 1995, 283). The sherds from Holyrood could be the earliest examples in Scotland, dating to the late 14th or early 15th century. They were recovered from the deep soil layer (Phase 2) overlying the earlier ditch fills, along with sherds of Scottish East Coast White Gritty Ware, Humber Ware and a sherd of Langerwehe Stoneware.

Langerwehe Stoneware Three body sherds and a frilled base sherd (no 102) were recovered. A large assemblage of Langerwehe Stoneware was recovered from excavations on Edinburgh's High Street, where they were dated to the mid 14th century (Scholfield 1974, 199). Some sherds were also recovered from excavations at Edinburgh Castle (Will 1997, 140).

Raeren Stoneware Two sherds of Raeren-type stoneware were recovered. These vessels generally date to the 15th and 16th centuries and were part of a large German stoneware industry. Unfortunately the sherds are too small to allow identification of the vessel type, but were probably part of a flagon or drinking mug.

Low Countries Redware One handle sherd, possibly from a cooking pot was recovered. These vessels were made at a number of production sites in the Low Countries and appear in increasing numbers on British sites from c 1350.

Modern pottery

Sixteen sherds of factory-made white and red earthenware and industrial stoneware were recovered. These sherds represent an ink bottle, plates and dishes. This material could have come from a number of factories throughout Britain.

Catalogue of illustrated examples (illus 8)

- 99 Five sherds of Scottish East Coast White Gritty Ware; pellet decoration. Context 3 (Phase 2).
- 101 Two sherds of Andalusian fine ware; flask/vase; late 14th/early 15th century. Context 3 (Phase 2).
- 102 Four sherds of Langerwehe; one frilled base. Context 3 (Phase 2).
- 121 One sherd of impressed, decorated floor tile. White fabric with green glaze. Panther(?) design. 13th century. Context 50 (Phase 2).
- 134 One sherd of impressed, decorated floor tile. White fabric with green glaze. Horse(?) design. 13th century. Context 74 (Phase 2).

ARCHITECTURAL FRAGMENTS

Two slabs of roughly worked sandstone were recovered, one (340 mm by 290 mm) from the deep soil layer overlying the ditch (Phase 2, context 50), the other (420 mm by 220 mm) from an earlier rubble fill of the ditch (Phase 2, context 71). Only one finely worked fragment was recovered; this was a stone from the deep soil layer (Phase 2, context 50), bearing a foliate/berry motif. In addition to the three stone fragments, a fragment of plaster with traces of gilding was recovered from a grave fill (Phase 3, context 40).

FLINT

Five fragments of flint were recovered from a variety of contexts. These included a possible gun flint (no 136) and one other worked fragment (no 140).

- 136 Fragment of toffee yellow flint with abraded edges. Possible a broken gun flint. From the fill of a modern pit, context 15 (Phase 6).
- 140 Fragment of grey flint with signs of outer cortex. Pronounced platform and blunting retouch on one edge. With Sk 58 (Phase 4).

HUMAN BONES

Christopher Hazel

Thirty-three individuals were identified from amongst disarticulated and loose remains. All human bone, including the disarticulated remains was analysed. Osteological and paleopathological analysis of individual inhumations involved recording the elements and fragments present and the state of preservation. Long bones and crania were measured and the presence of non-metric traits was recorded. Ageing characteristics were noted including epiphyseal and cranial fusion; diaphyseal and illial growth; dental development and pubic and auricular surface changes. Sex related morphology and measurements were noted for adolescents and adults. Living stature was calculated and averaged from all available long bones. Finally the anatomical location, distribution, stage of development and overall severity of any dental or skeletal anomalies and pathologies were recorded.

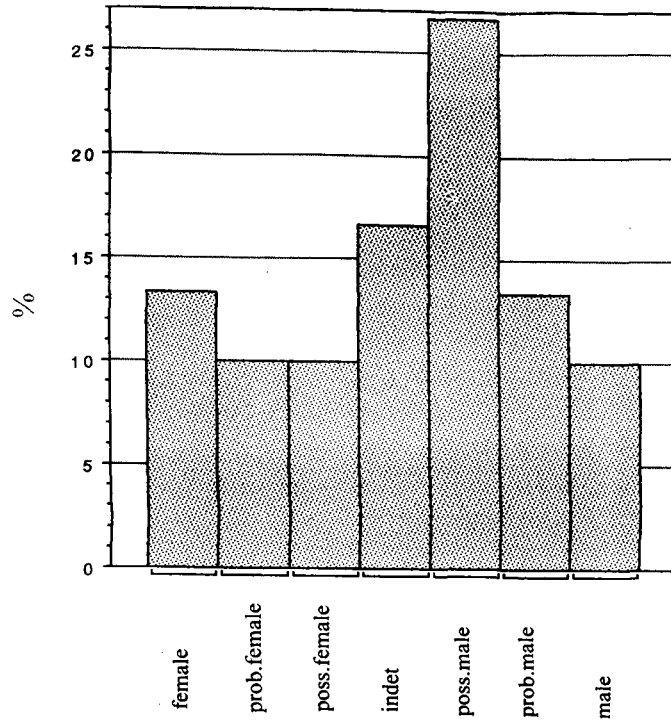
Of the 33 individual inhumations recognized, only four were 80–100% complete, eight were 60–79% complete, eight were 30–59% complete and the remaining 13 were under 30% complete. Diagenesis and pre-excavation disturbance left the bones in fair to poor condition with nearly every element suffering some abrasion and fragmentation. Nonetheless, the preservation of many small and fragile elements suggests that soil conditions were good for preservation of bone. Many elements from individual inhumations are missing, especially crania, and additional elements are present within the grave fills. This suggests that grave cross-cutting and crowding in the cemetery was the primary factor. There is no doubt that the graves of earlier occupants were disturbed to accommodate later inhumations (illus 4). Water damage (a burst water main) and unavoidable stress of excavation and post-excavation processing would have led to some abrasion but was apparently only a factor among the infants and foetus.

Sex (illus 9)

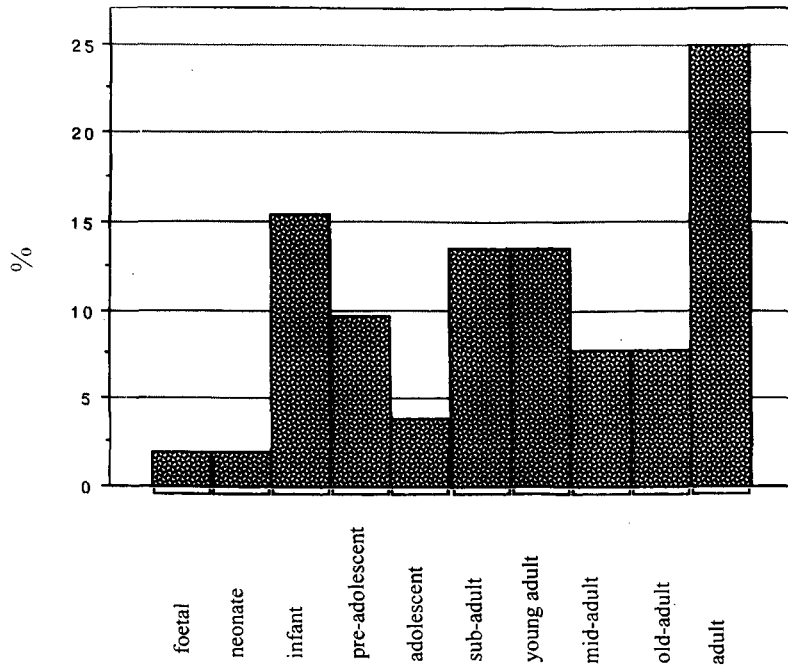
The lack of complete individuals (<12%) from the Holyrood sample posed a problem for accurate sex determination, and many individuals were ascribed an indeterminate status. The sexes are represented equally and indeterminate sex was most frequent due to poor preservation. Early adolescent and prepubescent individuals (<12 years) were not sexable, although methods for infant and child sexing have been proposed using illium measurements or comparing dental development and bone growth (Weaver 1991).

Age (illus 10)

The small sample from Holyrood made life-table analysis inappropriate, but does permit limited demographic interpretation (illus 10). The age distribution demonstrates three points. First, the presence of children and women from every age group supports the proposal that the cemetery was for the burgh population and not just for the convent of the Abbey. Second, infants are under-represented considering the high infant mortality in medieval urban populations, while young adults are over-represented (Manchester 1992). Two large (> 100) medieval samples from Glasgow Cathedral and Whithorn have similarly low frequencies of infants and children (King forthcoming; Cardy 1997, 521), but the high proportion of young adults remains peculiar to Holyrood. The lack of infants may reflect either selective burial or preservation, as their small bones may easily be scattered when graves are disturbed and are also easily lost or damaged during excavation. The young adult mortality does not appear to be gender specific and cannot



ILLUS 9 Sex distribution of adult skeletons



ILLUS 10 Age at death distribution of all skeletons

be attributed to either childbirth stresses or warfare as both sexes are equally represented. However, the number of individuals is too small to draw further conclusions.

Stature

Stature determination was possible in 15 cases. The average stature for females (N = 4) is 1.55 m and is 1.65 m for males (N = 11). When compared to a medieval population excavated at Glasgow Cathedral (1.54 m and 1.74 m) and Whithorn (1.56 m and 1.70 m) the results show little significant difference (King forthcoming; Cardy 1997, 522). The low number of measurable long bones of females does not permit further speculation but the low stature for men may reflect environmental stress during puberty. Alternatively, the 'possible' males may have been mis-sexed, thus skewing the stature average for men.

Cranial/infra-cranial indices

The few available infra-cranial indices from Holyrood conform to the data from medieval Whithorn (90% platymeric, 45% mesocnemic) (Cardy 1997, 523) and to femoral indices from St Helen-on-the-Walls (86% platymeric) (Dawes 1980). An average cranial index of 75.6 (mesocrany) was found in 61% of Whithorn crania (Cardy 1997, 522) and was also the mean from Glasgow (King forthcoming). Cranial indices 1–4 show a broad nasal cavity, narrow orbits and broad palate as the facial characteristics of Holyrood, unlike the narrow nasal cavity and wide orbits of the Glasgow Cathedral sample (King forthcoming). The overall absence or fragmentation of the crania, femora and tibiae at Holyrood make any statistically significant analysis impossible, but one may at least note the variability of such characteristics even within relatively small geographic areas.

Non-metric traits

Non-pathological variations and skeletal anomalies which did not affect survival are thought to indicate familial and population affinities. The non-metrics of this sample were inconclusive. Non-metric traits were not shared, for instance, by three skeletons within a single grave cut (Sk 55, 58 & 59), identified by the excavator as a possible family group.

Dental pathology

The sample from Holyrood contained 227 permanent and 95 deciduous teeth from 34 mandibles and 16 maxilla. Only two individuals (Sk 16 & 59) have complete dentition. Dentition was lost ante-, peri- and post-mortem, but post-mortem loss is probably the leading factor.

Congenital anomalies Sk 44 has maxillary third molar agenesis. This is thought to be the result of the evolutionary shortening of the mouth and is more common in gracile women. A permanent left mandibular second molar from the disarticulated remains has an enamel pearl (3 mm by 1 mm), on the lingual root surface.

Developmental abnormalities The infant Sk 59 has two unusual and possibly associated developmental defects. The developing enamel of the unerupted mandibular and maxillary second molars are pitted on all sides and discoloured grey-blue. Another infant, Sk 18a, also has similar discoloration of the mandibular

dentition. This discoloration and porosity may be caused by necrosis in the pulp cavity during development (Ortner & Putschar 1981). A solitary right mandibular second pre-molar (Sk 60) appears to have excessive deposition of cementum surrounding the root which is a potential sign of starvation or malnutrition related to childbirth stress.

Trauma The maxillary left first pre-molar and right second incisor of Sk 14, and the left maxillary second pre-molar have ante-mortem enamel fractures. It is possible that the pre-molars may have been pathologically weakened as the associated molars in both cases have moderate caries. Continuous abrasion of the enamel — through natural wear or other factors — will also break down a tooth. First and second molars from Sk 12 & 44 suffered extreme wear; the maxilla have corresponding carious infection. The loss of other molars also increases the wear on the remaining teeth and may play a part in wear, ante-mortem loss and M3 agenesis on Sk 12 & 44. Ante-mortem tooth loss observable on the mandible of Sk 12 and a left mandible from the topsoil (ie unstratified) may be an indirect result of trauma or wear, but are more likely to be the effects of infectious destruction. The unusually severe wear of the maxillary deciduous second molars from Sk 53 may be pathological, as diet would have abraded the other dentition.

Infectious reactions The crystallization of saliva and sugar-eating bacteria and their waste on the tooth surface (calculus) is an initial form of dental infection and is the foundation for dental caries. Calculus was severe with 64% of the dentition affected and 34% with heavy deposits. 51% of the deposits were on the buccal surface of the maxillary teeth and on the lingual and distal surfaces of the mandibular teeth, corresponding to the location of the salivary glands in the mouth. Four adults (Sk 12, 14, 16 & 25) of various ages and both sexes display evidence of periodontal disease in the form of bone recession. All display carious lesions and three have calculus confirming the connection between these pathologies.

Pitting of the enamel surface (caries) has many causes including calculus, periodontal disease, poor diet, attrition and improper hygiene. 19% of individuals from Holyrood have carious teeth. Though sex was not a significant factor, three sub-adults had caries of the permanent dentition suggesting either severe dietary stress (a diet rich in sugar/starch) or a congenital weakening of the enamel. A high frequency of caries in the young was also observed in the medieval sample from Glasgow Cathedral (King forthcoming).

Two adults have abscesses within the maxillary alveolar bone. The abscess of Sk 44 drained into the mouth while the abscess of Sk 14 drained into the maxillary sinus. Both individuals have hypoplastic lines, calculus, periodontal recession and multiple caries suggesting prolonged and painful affliction. Unfortunately, the infra-cranial skeleton of Sk 14 is not complete, prohibiting any diagnosis of systemic malnutrition resulting from dietary stress. The cribra orbitalia (iron deficiency) of Sk 44 conforms to a picture of an unbalanced diet, perhaps only soft starchy foods because of mouth pain.

Skeletal pathologies

Long-term disease processes and trauma may leave traces on human bone. With a complete skeleton, diagnosis of specific afflictions is possible, but the erosion or loss of elements from the Holyrood sample eliminates certainty in most cases. Each potential disease type will be discussed in relation to individual lesions and related to other burials. Typologies include neoplasias, infections, degenerative joint disease, trauma and metabolic or circulatory disturbances.

Neoplasias An enamel pearl 'cancer' neoplasia was observed on the root of the mandibular M1, recovered from topsoil. The right tibia of a sub-adult (6–9 years from metric analysis) has an unusual lesion with the appearance of pyogenic osteomyelitis. Though there are two 'cloaca' or drains of pus visible on the anterior mid-shaft surface, the extreme localized distortion of the surrounding bone gave the impression of a 'green-stick' fracture. An X-ray showed neither to be the case. First, there was no intrusion into the medullar cavity necessary for osteomyelitis. Second, there was no evidence of trauma and, considering the age of the

individual, insufficient time had elapsed for re-modelling. The homologous, localised and thickened cortical bone extending beyond the area of the lesion, and the well-defined circumscription of the lesion on the radiograph are highly suggestive of a benign osteoid osteoma (Ortner & Putschar 1981). This benign lesion would have been palpable through the skin but should not have spread to other more vital and sensitive body systems.

Trauma One remarkable example of trauma was discovered on an adult (possibly male) occipital. A 'key-hole' perforation left and inferior to the occipital protuberance was observed externally. Internally, a well-defined eburnated groove extends 80 mm right and inferiorly through the cruciate eminence. An X-ray showed no heavy metal infiltration, eliminating the possibility of a musket ball or lead-shot injury. Forensic pathologist Mary Cassidy (Glasgow University) and forensic anthropologist Anthony Forde (Trinity University) suggested the groove was a blade injury.

Arms specialists at Kelvingrove Museum, Glasgow, and the National Museums of Scotland, Edinburgh, were consulted to identify a blade which would match the head injury. The singular, curved, dull edge of this single-bladed injury could well have been made by a Scottish 'bollock dagger' (R Savage, pers comm). The injury perforated the cerebrum to only 60–70 mm, but would have ruptured the medulla oblongata, causing instant death. The conditions necessary for this sort of injury do not conform to those inflicted during a *mêlée*. The force necessary for such a wound, the location at the back of the head, and the low angle of entry combine to suggest that the individual was disabled and the head bent forward, in readiness for execution (R Savage & A Forde, pers comms). The only report at Holyroodhouse of an 'execution' with a blade is that of David Rizzio in 1566. Unfortunately, no other cranial or infra-cranial elements were associated with this occipital, which was recovered from the fill of a modern cut feature (Phase 6, context 15).

Stress indicators Arrested development of the long bones at times of immunal stress are similar to dental enamel hypoplasias in etiology and time of occurrence (ie in sub-adults). Unlike enamel, the cortex and medullary cavity of long bones continuously re-model throughout life and the arrest lines, or 'Harris lines', may be re-absorbed. Harris lines were counted from the radiographs of the tibiae of Sk 10 and one disarticulated example (context 11), and from the femora of Sk 25, 53 & 55. As expected, the adult long bones had no Harris lines. The disarticulated tibia had three lines, at both distal and proximal metaphyses, and the right femur of Sk 53 had five lines on the distal metaphysis. The stressors necessary for repeated arrested growth are also represented by evidence for rickets in Sk 53 (below) and a neoplasia of the disarticulated tibia.

Cribra orbitalia is a porotic lytic lesion on the orbital surface of the frontal lobe resulting from an iron-deficient diet, or from other stresses which result in a loss of iron from the body (eg mineral stores lost during menopause, haematogenous disorders and traumatic bleeding). Two adult females (>35 years) and a neonate exhibit these lesions. The life stages of these individuals fit the etiology of cribra orbitalia, being either menopausal or susceptible to childhood immuno-weakness.

Rachiteria (rickets) A deficiency of Vitamin D inhibits calcium deposition within the bone matrix and leads to further absorption of calcium from the bone. The condition undermines the structural integrity of bone, causing the shafts to bend under normal stress. The condition may resolve, but the distorted shape is retained leading to compensatory bone formation stabilising the bone. Sub-adults between six months and two years are primarily affected because of their rapid bone remodelling and acute susceptibility to socio-environmental stresses.

The femora of a six-year old (Sk 53) exhibit lateral bending (12–15 degrees) along the medial shafts. In addition the *linea asperae* are remarkably thickened and new bone is visible along the posterior surface of the shafts. An X-ray showed an increased thickening of the lateral cortex, suggesting structural compensation for the distorted shafts. Both humeri exhibit non-specific periostitis on the proximal shafts, possibly the

porous bone deposition associated with Vitamin C deficiency, leading to scurvy (Ortner & Putschar 1981). The deciduous teeth have a large amount of calculus and carious lesions, as well as severe wear of the deciduous second molar, suggesting delayed tooth loss; this is also a sign of dietary or disease stress. It is likely that this child suffered from metabolic disorders from early in life, overcoming rickets but still suffering from a deficient diet; this left traces on the dentition and may ultimately have led to death. An alternative explanation for these pathologies involves chronic gastro-intestinal disorder (eg dysentery or stomach flu). Intestinal illness would inhibit the consumption of nutritious foods, leading to delayed development and vitamin deficiencies. Repeated vomiting increases mouth acidity, thus stimulating calculus formation and weakening the enamel; this might explain the caries and wear on the deciduous molar. Illness involving bacteria, rickets or other metabolic disorders appears to have been common among children in urban medieval populations (Manchester 1992).

Non-specific infections Some form of non-specific periostitis or osteomyelitis has been observed on 50% of the individual inhumations and ten examples were found on the femora, tibiae and fibulae from the commingled remains. The most frequent location of periostitis was the shaft and metaphyses from the tibia (44%), femur (23%) and fibula (21%). The tibia and fibula also displayed the most severe periostitis and osteomyelitis. New bone formation on the mastoid and external auditory meatus of both temporals from one infant (Sk 20) is commonly referred to as tympania dehiscence; this results from chronic ear and sinus infection. The porosity of the maxillary sinuses of another infant (Sk 24) is typical of sinusitis, a non-specific infection related to chronic respiratory disease. The sinusitis, and the maxillary abscess of a third infant (Sk 14) draining into the sinus, indicate that illness from non-specific bacterial infection was present among sub-adults. The inferior surface of the proximal metaphysis of the right clavicle of Sk 25 has a perforation indicative of pyogenic osteomyelitis observable on X-ray, as well as bilateral periostitis of the shafts of both femora; the cloaca of the clavicle drained into the thoracic cavity and may have weakened the immune system. The entire left tibia and fibula of Sk 10 has extensive and severe periostitis; the tibia also has extreme osteomyelitic bone apposition with five cloaca draining from all sides of the shaft. Radiography showed no sign of trauma, but the bone formation on the surface and within the medullary cavity may mask a fracture. The tibia of Sk 10 indicates non-specific long-term infection which would have stressed the individual's immune system.

Osteoporosis Osteoporosis is associated with older adults (> 40 years) but its diagnosis in palaeopathology is often confused with other lytic ailments or post-mortem damage. An osteoporotic bone is very light and appears porous with thin cortices. Fifty-six vertebrae have some porosity. The thoracic and lumbar vertebrae of Sk 55, 47 & 56 have extensive porosity on superior and inferior surfaces. The vertebral bodies of Sk 56 are particularly light, but post-mortem damage (poor preservation) is a possible factor here. The pubic and auricular age-at-death of both individuals exceeds 40 years, corresponding to the pathogenesis of osteoporosis. Both sexes are represented equally.

Degenerative joint disease (DJD)

This is 'a disorder of . . . joints characterized by deterioration and abrasion of articular cartilage and formation of new bone at the joint surfaces' (Steinbock 1976, 278). Osteoarthritis, osteophytosis and general joint degeneration of the mobile union of two or more bones is a part of the ageing process but may be heightened by repetitive actions, genetic factors or auto-immune disorders. Non-specific infection and DJD make up 90% of all bone pathologies.

Spinal joint disease The vertebral column is highly susceptible to DJD, the degeneration of these joints may result in the ossification of elements to protect the spinal cord from rupture. A total of 236 vertebrae are at least partly present in this sample, with 52 cervical, 117 thoracic and 66 lumbar vertebrae from adults

and sub-adults. Some form of spinal DJD was observed on 26% of the skeletons. All adult ranges and both sexes are represented, but there were twice as many male sufferers than females, and mature adults have far more severe and diffuse degeneration than young and mid-adults.

Under stress the spongy bone of the body will change to maintain the most stability (Ortner & Putschar 1981). The lower thoracic vertebrae of Sk 47 are depressed anteriorly. The osteophytic lipping between the bodies shows a similar compression of the intervertebral discs. The individual would have had a slightly flexed posture, or 'kyphosis'; no other signs of DJD are observable on the appendicular skeleton. The etiology is unclear (the skeleton is incomplete), but may be related to osteoporosis and normal ageing. In Sk 55, the left-sided compression of thoracic 12 and lumbar 1–4 & 5 is compounded by osteophytic lipping and Schmorl's nodes. The irritation caused by the severe osteoarthritis in the right hip may have resulted in a reliance on the left leg. To favour one leg requires one to lean on the opposite side. The use of a crutch or cane on the right side would have had an inverse affect on the vertebral bodies. Therefore the pain of the osteoarthritis of the hip was not so debilitating as to require disuse of the left leg or the use of prosthetics. The eburnation on the right femoral head supports this hypothesis.

Schmorl's nodes There are 10 individual vertebrae with Schmorl's nodes from a total sample of 236. As with spondylosis deformans, mature adults have a greater frequency and severity of this. Many of the nodes of Sk 47, 55 & 56 are quite large, forming trough-like or cruciate depressions which appear to empty into the vertebral foramen. These are thought to be confluent, multiple nodes (Cardy 1997, 532). The size, between 2 mm and 10 mm, and multiple lesions found among all three individuals suggest that long term degeneration of the discs was taking place, but how they relate to other vertebral changes is ambiguous.

Vertebral osteoarthritis Vertebral osteoarthritis was present on five individuals (Sk 18b, 31, 47, 55 & 56). As with all spinal DJD in this sample, this primarily affected mature adults. The young and mid-adults (ie Sk 18b & 31), had only slight porosity of articulations. The only evidence of eburnation was found on the right articular facet of T4 from Sk 47. The rib articulations of Sk 56 had diffuse porosity and osteophytic lipping, corresponding to the arthritic rib facets and tubercles. Again, the etiology is usually old age.

Vertebral osteophytes Osteophytes (bony outgrowths) form in response to inactivity and/or inflammation of a joint, eventually fusing the union. 21% of the total vertebrae recovered from Holyrood were affected. The osteophytic lipping of Sk 47, 55 & 56 had not progressed sufficiently for fusion. The skeletal manifestation of diabetes — diffuse idiopathic skeletal hypertosis (DISH) — displays right-sided osteophytic lipping as observed on the lumbar vertebrae of Sk 55 & 47. DISH also produces diffuse extraneous bone throughout the system. Sk 47 has enthesopathies (tendon ossification) on the phalangeal diaphyses. Sk 55 has enthesopathies on the muscle attachments on the left forearm, both femora and the left patella. The osteophytosis, Schmorl's nodes, osteoarthritis and osteoporosis of Sk 55 are related to old age and stress. Sk 48 and a partly disarticulated vertebral group (context 51) have unusual osteophytic lesions on the sacral and fifth lumbar bodies respectively. They appear to be the initiation of fusion of the L5–S1 joint, suggesting 'sacralization' of the fifth lumbar. This process may involve stabilization of the joint in response to mechanical stress or a developmental anomaly.

Diarthroidal joint arthritis (DJA) The three osseous manifestations of DJA are osteophytic growth along the border of the joints, and porosity and eburnation of the joint surface. Five adults had degenerative joint lesions and 19 examples of DJA were found among the comingled remains. Four of the five inhumations with DJA (Sk 9, 12, 48 & 56) exhibit either osteophytic changes to the first tarso-phalangeal and inter-phalangeal joints or osteoarthritis of the acromio-clavicular and gleno-humeral joints. The lesions on Sk 9, 48 & 56 would have caused stiffness in the 'big toe' and could have resulted from the normal stress of locomotion. The age, location and spurring of the DJA on the right and left hand fingers (right 1st & 5th, left 1st & 4th) of one mature adult (Sk 56) correspond to the pattern for osteoarthritis, causing stiffness and

pain. Osteoarthritis of the shoulder can result from heavy manual labour or old age and is often an indicator of handedness. The DJA on the shoulder of two mature adults (Sk 12 & 56) did not inhibit use of the right arm, but may have caused some stiffness or pain when lifting objects.

The DJA of Sk 55 is extensive, affecting all the joints involved in bipedal locomotion. The extensive destruction, remodelling and eburnation of articular surfaces of the right hip, the osteophytosis and enthesopathy on the left hip, the osteophytosis and malformation of the spine, focal destruction and osteophytes on the left patella and foot and, finally, other diffuse enthesopathies, present an enlightening pattern of osteoarthritis. The severity of the degeneration on the right hip is similar to pyogenic septic arthritis, but there is not sufficient distortion of the articular space nor a clearly defined 'drain' for pus to support this diagnosis. The right hip of this individual sustained no visible trauma, but must have been overstressed at some point long before death. Compounded by age (40–50 years), the degenerated joint would have been a continuous annoyance at best, or an incapacitating illness at worst. The individual continued to use the arthritic hip, but may have compensated for stiffness and tenderness by leaning to the opposite side. This theory is supported by the left-sided compression of the vertebral bodies and DJA, osteochondritis dissecans (below) and enthesopathy on the left leg and right pubis, indicating aberrant repetitive movement (ie a limping gait).

Enthesopathies Enthesopathies were observed on three individuals (Sk 17, 55 & 56) and on eight elements from the comingled remains. These formations appear to be associated with senile ossification of connective tissue (in Sk 55 & 56) and muscular stress (in Sk 55).

Osteochondritis dissecans (OCD) This circulatory condition creates small necrotic areas on the articular surfaces of diarthroidal joints which become dislodged, drifting within the joint capsule and leaving behind perforations. There are nine possible examples of OCD from five individuals and comingled remains from Holyrood. The distal tibia of Sk 55 has a perforation (diam 2 mm) similar to OCD, and the patella has an oval formation on the articular surface, raised 2–3 mm, which appears to be a re-implanted OCD osteoid. Four examples of OCD were discovered on the proximal surface of the first proximal tarsal phalanges from Sk 16, 32, 38 & 56. All four smooth-edged perforations measured from 2 mm to 4 mm in diameter. It is interesting to note that all four individuals were female. The occurrence of this circulatory disorder exclusively within the lower appendages is related to the stress of locomotion and the relatively poor circulation of the lower legs and feet. Gender-specific activities or hormones may also be factors.

Summary

Several factors have limited the scope of this report. The lack of complete skeletons (only four were 80–100% complete) and the universal abrasion and fragmentation of the bones prohibited more precise age-at-death, sex and living stature determinations, as well as pathological diagnoses. The 33 individuals (51 including comingled remains) were varied and informative, but such a small sample cannot be used to formulate robust theories on the demography of the population, nor be reliably comparable with other cemetery populations.

Nonetheless, osteological analysis has revealed some insights into the demography of the Abbey and its burgh of Canongate. Nearly 50% of the cemetery population are sub-adults, as is the case among other contemporary Scottish skeletal samples. Glasgow Cathedral is an exception as, here, there were relatively few children (Cardy 1997; Cross & Bruce 1989). The Glasgow sample is thought to be made up primarily of élite individuals, however, thus excluding children (King forthcoming). In contrast, the sample from Holyrood Abbey appears to represent the burgh of Canongate and not the convent of the Abbey or the royal household. The high proportion of young adults at Holyrood supports this proposal, since individuals of a higher

social/economic status, having once survived childhood diseases, would generally have lived much longer than their less privileged contemporaries. Stature averages for women (1.55 m) and men (1.65 m) were generally comparable to other Scottish samples, though men were slightly shorter than the norm, perhaps reflecting differences in health and diet, or possible mis-identification of sex in some individuals.

Pathological analysis recorded evidence for frequent dental disease related to diet, hygiene and development, diffuse non-specific infection related to general immune stress, and degenerative joint disorders of the lower vertebrae and appendiculars, apparently resulting from natural ageing and mechanical stresses.

The numerous caries, periodontal disease and calculus suggest that a starchy diet and poor oral hygiene was the norm at Holyrood and would have lead eventually to total tooth loss, as seen on one mandible from the commingled remains. Dental attrition was pronounced, but corresponded to other ageing results, so that the rate of wear and the general diet were similar to that of Miles' (1963) prehistoric British population.

Skeletal pathology was not unlike that seen in other urban medieval populations. The frequency (45%) and location (tibia and fibula) of periostitis of the skeletal remains from Holyrood is typical of urban populations. In fact, the location of degenerative joint disease primarily on the lower vertebrae and the diarthroidal joints of the legs, and the mature age of the individuals most extensively affected, corresponds with the pattern of this general disorder among 20th-century urban populations, as well as other medieval samples.

The pathology of the sample also reveals information on the population's response to illness. The evidence of metabolic disorder and dental malformation of one sub-adult (Sk 53) related to possible intestinal illness, the sinusitis of a child (Sk 24) and the tympania dehiscence of an infant (Sk 20) all attest to the ill-health of children in medieval Scotland. The chronic illnesses of the children is a tale of suffering, but it also implies that they had some form of medical care permitting survival beyond the acute phase of the disease. The osteoarthritis of Sk 55, chronic osteomyelitis of Sk 10 and osteochondritis dissecans of four women (Sk 16, 32, 38 & 56) demonstrates the tenacity of some individuals in the face of painful and debilitating illnesses.

MAMMAL AND BIRD BONE

Tanya O'Sullivan

The animal and bird bones came primarily from two ditch fills (Phase 2), contexts 67 & 71. (A substantial number of human bone fragments were also included in these fills.) The species represented were cattle, sheep, roe deer, pig, horse, domestic fowl, domestic goose, unidentified wader and rabbit. The bones were in good condition and it was possible to take a number of proximal and distal breadth measurements on the long bones. Unfortunately, minimum number analysis indicates that only one was present from each context.

Mammal bones The sample consists mainly of butchered remains of cattle and sheep. Most skeletal elements are represented including skull, mandible, teeth, lower leg and toe bones as well as the good meat bones, ie scapula and upper limb bones. Recurrent butchery marks such as the vertical splitting of articular surfaces and longitudinal splitting of the long bone diaphyses on both cattle and sheep bones indicate the lengths to which the inhabitants went to procure every last morsel of marrow.

The presence of butchered horse bone at Holyrood is not unusual but does prompt the question of whether or not horse was consumed. Butchered horse bone has been noted at medieval sites in Inverkeithing and Perth (Smith & Hodgson 1983, 544; 1987, 197) and at Edinburgh Castle (McCormick 1997). It has

been suggested that the butchered horse bones at Edinburgh Castle represent periods of siege and were eaten in response to extreme food shortage. The horse bones did not, however, display as many butchery marks as the cattle and sheep, and one potentially good meat bone (a femur) was complete and without cut marks. It has been suggested that this may represent dismembered carcasses for disposal rather than for their meat (Baxter 1996, 71). No osteoarthritic conditions or traces of spavin (abnormal fusion of the tarsus bones) were noted on the hind limb bones, indicating that the animal — if it was kept for draught purposes — was not unduly overworked.

Pig is represented by only one unfused radius indicating an animal under three years. Pig played a minor role in the diet of medieval religious houses, as evident at Pluscarden Priory (McCormick 1994) and Dundrennan Abbey (O'Sullivan forthcoming) for instance.

The presence of only one deer bone is surprising, given the proximity of the site to the royal hunting reserve of Holyrood Park, and other nearby royal parks at Seton and Dalkeith (Gilbert 1979, 365). A single rabbit bone was also recovered, from the lower ditch fills (Phase 2).

Finally, two long bone fragments with secondary working and a sheep cranium with horn cores suggest bone- and hornworking on or near the site. These were also recovered from the lower fills of the ditch (Phase 2).

Bird bone Bones from domestic fowl and goose were present in the sample. Most of the fowl bones examined were immature, implying that these birds were eaten rather than kept for eggs. The preference for poultry meat is further demonstrated by the presence of a tarso-metatarsus with a spur scar; this probably came from a capon, or castrated cockerel (West 1982, 255), although this is not always the case (O'Sullivan 1990). Frequent documentary reference is made to domestic fowl in later medieval times. Poultry commonly features as an element of 'rents in kind', sometimes as a specified number of capons (eg Symon 1959, 339; Rogers 1880, 178), the only domestic bird of higher value being the domestic goose (Shirley 1926, 21).

Capon and domestic goose attest to a degree of affluence, therefore, in evident contrast with the information gleaned from the animal bone (albeit based on the very small sample), where a strain on resources is indicated by acutely butchered cattle and sheep bones, possible consumption of horse meat and minimal representation of pig and deer. However, as much of the bone was recovered from late (redeposited?) contexts, these comments need not apply directly to either the Augustinian convent or the royal household in the medieval period.

CONCLUSIONS

The small scale of the excavation obviously limited the amount of information retrieved and subsequently limits the conclusions one can draw. Nevertheless, some illumination of important events in the history of the Abbey and Palace can be derived from the archaeological record.

The early feature, a possible ditch, may have been the western boundary of an early churchyard pre-dating the Abbey but, pending further evidence for this, it must be considered more likely that it was a primary boundary to the Abbey precinct. The deliberate infilling of the ditch is interpreted as part of a programme of improvements, including drainage and enclosure, in the 14th century, reflecting the ongoing development of a major Abbey, provided with royal apartments and suitable to serve as a political as well as religious centre.

English invasions during the 14th century directly involved Holyrood on three occasions. The most serious episode was in 1322, when construction of the Abbey suffered a setback at the hands of Edward II's army. Historical records do not describe the effects of the attack in detail, but materials recovered from the excavation suggest that stained glass windows were smashed and architectural details damaged. Probably those fragments which were suitable for reuse were recovered but enough was left amongst the buried debris to offer a glimpse of the grisaille decoration of the original windows.

The human remains are typical of an urban medieval cemetery population, with articulated, supine skeletons lying amongst the disarticulated remains of earlier burials. From the limited sample available, it seems that all age groups and both sexes are equally represented. This suggests that these burials are neither from the monastic convent nor the royal household, but represent a more diverse and less élite population. This lends support to the identification of the area north and west of the Abbey church as the parish cemetery of Canongate; but the cemetery is also likely to include Abbey tenants and artisans employed on the construction of its buildings, as such a task could be a lifetime's occupation. The convent of the Abbey and the royal household would also have employed many people to attend to their needs, and these too may be potential occupants of the cemetery.

The continuing status of Holyroodhouse as an official royal residence in the post-medieval period is represented by the construction of a new range attached to the great tower in the 1670s. After the demolition of this building in the mid 19th century, the excavated area was occupied by a boilerhouse, a more prosaic reminder that Holyroodhouse was again a favoured royal residence, as the grounds were improved and the apartments modernized in the reign of Queen Victoria. Holyroodhouse today is still a royal residence, but also a major tourist attraction. The present excavation was a consequence of further upgrading and landscaping which allowed private gardens to be opened to the public. The excavation of substantial medieval deposits indicates that equally informative deposits survive in other areas of the present garden and paved forecourt.

ACKNOWLEDGEMENTS

The author would like to thank the excavation team — Andy Barlow, Irene Cullen, Ralph Troup and Gordon Turnbull — and also those involved in post-excavation work, some of whom kindly volunteered. The author is grateful to the staff at Holyroodhouse for providing facilities and for contributing to the smooth running of the excavation, particularly Tom Cuthbert of Historic Scotland and Lt Colonel Anderson, Superintendent of the Palace of Holyroodhouse. The illustrations were drawn by Keith Speller and Caitlin Evans. Finally I should like to thank my colleagues, in particular Nicola Battley, Stephen Driscoll, Heather James and Robert Will, who commented on the text. Thanks also to Amanda Cardy and Pamela Graves, who offered valued opinions on the human remains and window glass.

Historic Scotland provided funding for the excavation, post-excavation analyses and publication.

REFERENCES

- Aliaga-Kelly, C & Proudfoot, E 1995 'Floor Tiles in medieval and post-medieval Scotland', *Medieval Ceram*, 19 (1995), 67–77.
- Baxter, I 1996 'Medieval and early post-medieval horse bones from Market Harborough, Leicestershire', *Circaea*, 2 (1996), 65–79.
- Blair, J & Pyrah, C 1996 *Church Archaeology: research directions for the future*. York (=CBA Res Rep, 104).
- Bowler, D, Cox, A & Smith, C 1995 'Four excavations in Perth, 1979–84', *Proc Soc Antiq Scot*, 125 (1995), 917–99.
- Bryce, W M 1914 *Holyrood: its Palace and its Abbey*. Edinburgh.
- Caldwell, D & Dean, V 1992 'The pottery industry at Throsk, Stirlingshire in the 17th and 18th century', *Post-Medieval Archaeol*, 26 (1992) 1–47.

- Cardy, A 1997 'Human bones', in Hill, P *Whithorn and St Ninian: the excavation of a monastic town 1984–91*, 519–60. Stroud.
- Cavers, K 1993 *A Vision of Scotland: the nation observed by John Slezer 1671 to 1717*. Edinburgh.
- Cross, J F & Bruce, M F 1989 'Skeletal remains', in Stone, J A (ed), *Three Scottish Carmelite Friaries: Aberdeen, Linlithgow and Perth*, 119–41. Edinburgh (= Soc Antiq Scot Monogr Ser, 6).
- Dawes, J D 1980 'Human bones', in Dawes, J D & Magilton, J R (eds), *The Cemetery of St Helens-of-the-Walls Kirk, Aldwark*, 19–82. York.
- Driscoll, S T & Yeoman, P A 1996 *Excavations within Edinburgh Castle, 1988–1991*. Edinburgh (= Soc Antiq Scot Monogr Ser, 12).
- Fawcett, R 1992 *The Palace of Holyroodhouse*. Edinburgh.
- Fawcett, R 1994 *The Architectural History of Scotland: Scottish architecture from the accession of the Stewarts to the Reformation, 1371–1560*. Edinburgh.
- Gabra-Sanders, T 1995 'Lace tag', in Lewis & Ewart, 88.
- Gerrard, C M, Gutierrez, A, Hurst, J G & Vince, A 1995 'A guide to Spanish medieval pottery', in Gerrard, C M, Gutierrez, A & Vince, A, *Spanish Medieval Ceramics in Spain and the British Isles*, 281–95. Oxford (= BAR Int Ser, 610).
- Gilbert, J M 1979 *Hunting and Hunting Reserves in Medieval Scotland*. Edinburgh.
- Graves, C P 1995 'Window glass', in Lewis & Ewart, 110–13.
- Haggarty, G 1980 'Pottery', in Ewart, G 'Excavations at Stirling Castle, 1977–78', *Post-Medieval Archaeol*, 14 (1980), 36–46.
- Haggarty, G 1984 'Observations on the ceramic material from Phase 1 pits BY and AQ', in Tabraham, C, 'Excavations at Kelso Abbey', *Proc Soc Antiq Scot*, 114 (1984), 395–7.
- Hare, J N 1985 *Battle Abbey: the eastern range and the excavations*. London (= HBMC(E) Archaeol Rep, 2).
- Harrison, J 1919 *The History of the Monastery of the Holy Rood*. Edinburgh.
- Holdsworth, P (ed) 1987 *Excavations in the Medieval Burgh of Perth 1979–81*. Edinburgh (= Soc Antiq Scot Monogr Ser, 5).
- Hurst-Vose, R 1988 'Window glass', in Reid, A G & Lye, D, 'Pitmiddle Village and Elcho Nunnery', *J Perthshire Soc Natur Sci*, 44 (1988), 49–84.
- King, S forthcoming 'Human bone', in Driscoll, S T, *Excavations at Glasgow Cathedral*.
- Knight, B 1985 'Lead comes', in Hare, 154.
- Lewis, J & Ewart, G J *Jedburgh Abbey: the archaeology and architecture of a Border abbey*. Edinburgh (= Soc Antiq Scot Monogr Ser, 10).
- MacAskill, N L 1983 'Pottery', in Wordsworth, J 'Excavations in Inverkeithing, 1981', *Proc Soc Antiq Scot*, 113 (1983), 535–42.
- McCarthy, M R & Brooks, C 1988 *Medieval Pottery in Britain AD 900–1600*. Leicester.
- McCormick, F 1997 'Faunal remains', in Driscoll & Yeoman, 201–12.
- McCormick, F 1994 'Animal bones', in 'Excavations at Pluscarden Priory, Moray', *Proc Soc Antiq Scot*, 124 (1994), 391–432.
- Manchester, K 1992 'The palaeopathology of urban infections', in Basset, S (ed), *Death in Towns: urban responses to the dying and the dead, 100–1600*, 8–14. Leicester.
- Maxwell, H 1934 *Official Guide to The Palace, Abbey-church and environs of Holyroodhouse*. Edinburgh.
- Miles, A E W 1963 'The dentition in the assessment of individual age', in Brothwell, D R (ed), *Dental Anthropology*, vol 5, 191–209. Oxford.
- Murray, H K & Murray, J C 1993 'Excavations at Rattray, Aberdeenshire: a Scottish deserted burgh', *Medieval Archaeol*, 37 (1993), 109–218.
- Oldrieve, W T 1912 'Holyrood Abbey Church: notes of recent excavations', *Scott Ecclesiol Soc Trans*, 1911–12. Edinburgh.
- Ortner, D J & Putschar, W G J 1981 *Identification of Pathological Conditions in Human Skeletal Remains*. Washington, D.C.

- O'Sullivan, T 1990 An Avi-faunal Analysis of the Bird Bone from Fishamble St, Dublin (= Unpubl MA thesis). University College Dublin.
- O'Sullivan, T forthcoming 'Animal bone', in Ewart, G *Excavations at Dundrennan Abbey*.
- Richardson, J 1929 'A 13th-century tile kiln at North Berwick, East Lothian and Scottish medieval floor tiles', *Proc Soc Antiq Scot*, 63 (1929), 281–310.
- RCAHMS 1951 Royal Commission on the Ancient and Historical Monuments of Scotland. *The City of Edinburgh*. Edinburgh.
- Robertson, J 1860 'Notice of a volume of the accounts of Sir William Bruce of Balcaskie, General Surveyor of His Majesty's Works (1674–1679)', *Proc Soc Antiq Scot*, 3 (1857–60), 113–16.
- Rogers, C 1880 *The Register of Coupar Angus Abbey*, 2 vols. London.
- Scholfield, J 1974 'Excavations south of Edinburgh High Street, 1973–4', *Proc Soc Antiq Scot*, 107 (1975–6), 155–241.
- Shirley, G W 1926 'Birds mentioned in the Acts of Parliament of Scotland 1124–1707', *Trans Dumfriesshire Galloway Natur Hist Antiq Soc*, 3 (3 ser) (1924–5), 4–46.
- Smith, C & Hodgson, I 1983 'The animal bone from No 1 Bank St/Nos 5–7 Town Hall St', in Wordsworth, J, 'Excavations in Inverkeithing 1981', *Proc Soc Antiq Scot*, 113 (1983), 542–5.
- Smith, C & Hodgson, I 1987 'Animal bone', in Holdsworth, 196–9.
- Steinbock, T R 1976 *Pathological Diagnosis and Interpretations*. Illinois.
- Symon, J A 1959 *Scottish Farming*. Edinburgh & London.
- West, B 1982 'Spur development: recognising caponised fowl in archaeological material', in Grigson, C, Payne, S & Wilson, B (eds), *Ageing and Sexing Animal Bones from Archaeological Sites*, 255–63. Oxford (= BAR Brit Ser, 109).
- Will, R 1997 'Medieval pottery', in Driscoll & Yeoman, 140–6.

This paper is published with the aid of a grant from Historic Scotland